

Age-Related Features Of Clinical Manifestation And Development Of Spinal Deformity In Scoliotic Disease

JURAEV Ilkhom Gulomovich

Samarkand State Medical University
University Associate Professor of the
Department of Traumatology and
Orthopedics, PhD. Samarkand, Uzbekistan.

ISHKOBILOV Rustam Dzhankhurozovich

Samarkand branch of the Republican Scientific
Center for emergency medical care with the
department of traumatology

Corresponding author: Juraev I.G. travma.km@mail.ru

Annotations

31 children with initial manifestations of spinal deformity were studied of varying degrees and severity of scoliotic disease. It has been established that the first clinical signs of spinal deformities appear at the age of no more than 10 years. those. before the beginning of the period of physiological maturation of the body. Analysis of the obtained data makes it possible to determine the proportions of various variants of the natural development of scoliotic spinal deformity. This makes it possible to predict the prospects for the development of pathology in patients with scoliosis.

Key words: children, scoliosis, spinal curvature, clinic, diagnosis.

For citation: Jurayev I. G., Ishkobilov R.Dz. Age-related features of clinical manifestation and development of spinal deformity in scoliotic disease. Journal of Biomedicine and Practice. 2024, Vol.____, issue____ pp.____

Introduction. In the nasological structure of children's orthopedics, scoliosis is one of the most serious diseases. Because this disease is characterized by the main of the set of orthopedic symptoms - a specific curvature of the spine, and it manifests itself clinically in childhood. According to many authors, the clinical picture of the initial signs of curvature of the spine in scoliosis is visible in children from the age of 5-7 [2,8].

But the symptoms of the disease can be observed relatively early at 3-6 years old or close to adolescence at 10-12 years old. This situation makes it necessary to classify the age of patients according to the stage of development of the disease [3,4,5].

Because, treatment methods are used based on information about bone growth process and its maturity [1].

It is known from the scientific literature that the growth process can negatively affect the future development of vertebral curvature. Therefore, the rapid development of this orthopedic disease is one of the factors that cannot be eliminated [1,2,3,9]. However, many clinical observations show that during the physiological development of patients with scoliosis, regardless of the age and the initial clinical picture, the curvature of the spine is manifested in various variants [5,6,7].

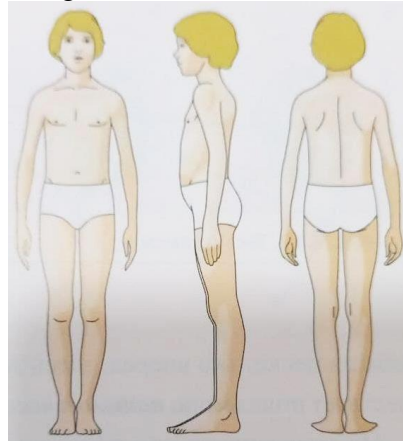
The purpose of the work: to evaluate and determine the age-related development of clinical signs of the curvature of the spine in patients with scoliosis.

Material and inspection methods:

The examination materials were carried out in the polyclinic of the Samarkand branch of the Republican Center for Traumatology and Orthopedics during the years 2015-2022. 22 (71.0%) of 31 patients aged 3-18 years who underwent orthopedic examinations with various degrees of spinal curvature were girls and 9 (29.0%) were boys (ratio 7:3). Patients were evaluated by X-ray imaging of the spine in the correct projection, upright and supine position along with clinical examinations. The curvature angle of the vertebrae was evaluated by the Cobb method.

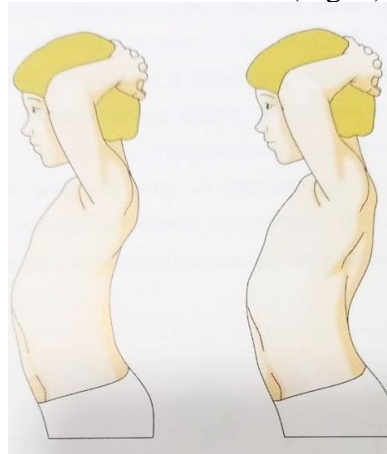
During the clinical examination, the patient's height is visually assessed from the front, side and back. In the initial stage of scoliosis, it is difficult to determine the curvature of the axis of the vertebrae in the frontal

plane in relation to the sharp-edged protrusions. When viewed from the front, it is not difficult to determine the disproportion of the lumbar triangle (Fig. 1).



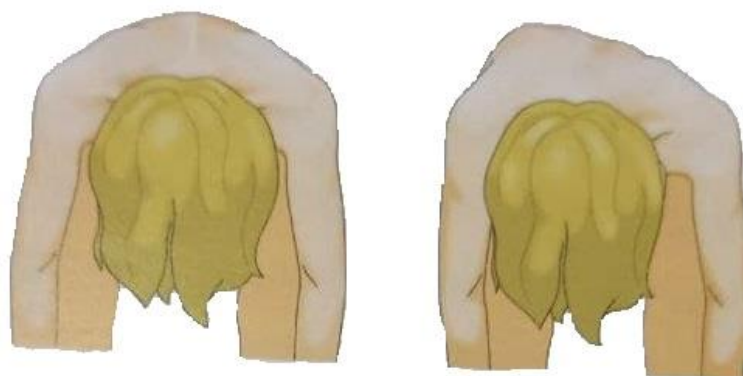
Picture-1. Front, side and back views of the patient's body during clinical examination

The patient's stature can be evaluated from the side in the sagittal plane, the functional state of the spine. It is not difficult to observe the physiological kyphosis of the chest when the patient's stature is relatively relaxed and the body is kept in an upright position. Also, it is not difficult to determine the kyphotic condition of the patient when he puts his hands on the back of his head (Fig. 2).



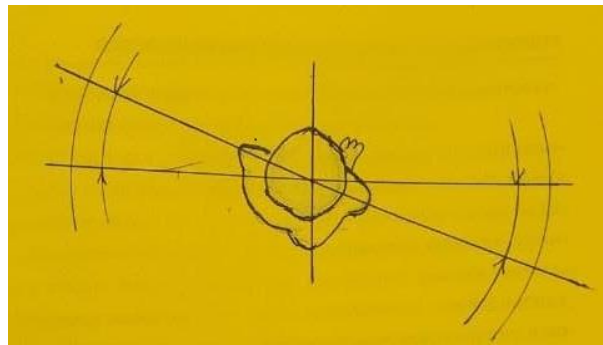
Picture-2. Patient condition in the diagnosis of physiological kyphosis.

A rotational (twisting) component can be determined when the spine bends in three planes. For this, the patient leans forward with his arms down. This condition is called the Adams method (test) and the proportion of the back of the chest is evaluated. The identified disparity is evaluated depending on which part of the vertebrae it corresponds to (Fig. 3).



Picture-3 . Assessment by Adams method.

Also, in the visual evaluation, the mutual proportion of the hip and shoulder girdle along the frontal axis is evaluated with the direction of torsion of the patient's body. In practice, orthopedists do not pay much attention to torso torsion from a clinical point of view. However, torsion of the body is important in the initial period of the disease. Because pathological rotation (twisting) of the vertebrae is observed during the development of the disease. As a result, the torsion of the body changes (Fig. 4).



Picture-4. A method of estimating body torsion (twist).

At the final stage, the child is asked to maintain the correct posture independently. All curvatures of the spine are mostly restored when the child maintains the correct posture. This method is a method of differentiating scoliosis from stature disorder. Also, to justify this situation, as a control, the child lays on his stomach and performs exercises that record the spine. If a child has a stature disorder, all symptoms disappear, but in case of scoliosis, they remain. That is, in the region of the vertebrae where the rotational component is observed, there is an imbalance due to the tension of the intervertebral muscles. That is, the Adams test is observed.

Results of X-ray examination V.D. It was evaluated according to the Chaklin classification. From the X-ray image (with the patient in a standing position), the main curvature angle in the frontal plane was 10 ° or less in the frontal plane in 17 patients. Level II (angle of arc of curvature 11-25 °) - in 7 patients, III level (the angle of the arc of curvature 26-40 °) was observed in 5 patients and IV level (41 ° and more) was observed in 2 patients.

Check results:

When analyzing the distribution of scoliosis patients by age (table-1), the disease was detected in 12 (38.7%) patients aged 11-12 years. In the second place are 9 (29.0%) patients aged 3-6 years and 3 (9.7%) patients aged 13-14 years, in the third place are 3 (9.7%) patients aged 9-10 years, in the fourth place are 4 patients aged 7-8 years (12.7%) patients. According to the data, there are 15 (48.9%) patients aged 11-14 years who are in the most accelerated period of physiological growth and are characterized by the transition to adulthood. There were 16 (51.1%) minors aged 3-10.

It was possible to determine the age at which the initial clinical signs of scoliotic curvature appeared from the medical history, when the patients talked with their parents after familiarizing themselves with the patients' polyclinic-ambulatory cards. According to the established data, the early symptoms of the disease were observed in the majority of patients at the age of 3-12 years before turning to the hospital. The child's age at which the symptoms of height disproportion appeared was determined in a conversation with the patient's parents.

Distribution of patients diagnosed with scoliosis at primary examination according to age, disease severity and degree of curvature

Table-1.

Severity of deformity at primary examination	Patient the number	3-6 yo un g	7-8 yo un g	9-10 youn g	11-12 young	13-14 young	Abs. the numbe r	General to the number ratio %

I (S - 10 °)	abs.	6	2	1	7	1	17	54.8
	%	19.3	6.5	3.2	22.6	3.2		
II (11-25 °)	abs.	3	1	2	-	1	7	22.6
	%	9.6	3.2	6.5	-	3.2		
III (26-40 °)	abs.	-	1	-	4	-	5	16.1
	%	-	3.2	-	12.9			
IV (41 ° and more)	abs.	-	-	-	1	1	2	6.5
	%				3.2	3.2		
Total abs. the number		9	4	3	12	3	31	100
in %		28.9	12.9	9.6	38.7	9.6	100	

III degree of the disease was detected in 5 patients aged 7-12 years (16.1%).

Severe IV degree curvature of the spine was detected in 2 (6.5%) patients, most of them were detected at the age of 11-14 years.

Analyzing the results of early detection and diagnosis of the disease, it became clear that the earlier the first symptoms of scoliotic curvature of the spine develop, the more aggressive the process of curvature during the patient's physiological growth, that is, the faster the disease develops, the worse the level of the disease. That is, if the first symptoms of the disease develop at the age of 3-4, the IV degree of scoliotic curvature is observed in 60-70%. If the symptoms of the disease develop at the age of 11-13 years, the IV degree of scoliotic deformation is not observed, and only in 16-21% of cases there is a possibility of observing the III degree of the disease.

Conclusions:

1. Clinical and X-ray observations showed that the appearance and development of the first symptoms of scoliotic curvature of the spine depend to a certain extent on the patient's age.
2. The first early symptoms of the spine were observed to develop mainly before the age of 10-11 years, that is, before puberty.
3. Determining the period of appearance and development of symptoms of the disease provides an opportunity to predict the future development process of scoliotic curvature of the spine in patients.
4. Early detection of clinical and radiological symptoms of the disease is the main factor for early treatment of the disease. This condition, in turn, makes it possible to reduce the rate of complications without aggravating the disease.

Used literature

1. Ахтамов А., Ахтамов А.А. Тошбеков А.Р. Идиопатик сколиозда умуртка поғонасининг қийшайиши ривожланишини динамикада болалар ёшига кура ўзига хос клиник манзараси // Тиббиётда янги кун 6/44/2022-йил. Стр. 133-138.
2. Казмин А.И., Кон И.И., Беленкий В.Е. Сколиоз. –М., 1981. 436с.
3. Михайловский М.В., Фоличев Н.Г. Хирургия деформаций позвоночника- Новосибирск. 2002. 356 с.
4. Тесаков Д.К. Возрастная динамика рентгенологических характеристик активности костного роста таза и позвоночника больных идиопатическим сколиозом. // Вестник травматологии и ортопедии им. Н.Н.Приорова. 2011. N 1. Стр 60-67.
5. Тесаков Д.К. Возрастные особенности клинического проявления и динамика развития деформации позвоночника при идиопатическом сколиозе // Вестник травматологии и ортопедии им. Н.Н.Приорова 2010. N 2. Стр. 61-65.
6. Чаклин В.Д., Абальмасова Е.А. Сколиоз и кифозы.-М., 1973.
7. Шатохин В.Д., Колчин Д.В., Колесов В.В. Ранняя диагностика и консервативное лечение сколиоза у детей: Пособие для врачей.- Толяти. 2005. 292 с.

8. Wang Y., Zheng G., et al. Temporary use of shape memory spinal rod in the treatment of scoliosis // Eur. Spine J. -2011. -N 20. -P. 118-122.
9. Mok J.M., Cloyd J.M., et al. Reoperation after primary fusion for adult spinal deformity: rate, reason, and timing // Spine. 2009. -N 34(8). -P. 832-839.10. Аширов М. У., Гиясова Н. К. МРТ При Болях В Пятке //Central Asian Journal of Medical and Natural Science. – 2023. – Т. 4. – №. 3. – С. 710-730.
11. Аширов, М. У., Усаров, М. Ш., & Шавкатова, Ш. Ш. (2022). Sinus Tarsi-Доступ При Переломах Пяточной Кости. Новый Золотой Стандарт?. Central Asian Journal of Medical and Natural Science, 3(5), 145-153.
12. Аширов М. У., Уринбаев П. У., Хасанов М. Э. Комплексные приёмы в методике лечения переломов пяточной кости на основе особенностей структуры стопы //Журнал теоретической и клинической медицины. – 2019. – №. 1. – С. 59-62.
13. Ибрагимов С. Ю., Аширов М. У. Результаты лечения диафизарных переломов пястных костей кисти //Актуальные проблемы травматологии и ортопедии: науч.-практ. конф. травматологов-ортопедов Узбекистана: тез. докл. – 2016. – С. 152-153.
14. Мансуров Д. Ш., Жураев И. Г., Мухсинов К. М. Перелом Тилло у взрослых: клинический случай и обзор литературы //Uzbek journal of case reports. – 2022. – Т. 2. – №. 1. – С. 7-12.
15. Gulomovich, J. I., Umirzokovich, A. M., Azizovich, T. K., & Sirojiddinovich, K. A. (2020). To A Question Of Operative Treatment No Accrete Crises And False Joints Neck A Hip. European Journal of Molecular & Clinical Medicine, 7(07), 2020.
16. Умирзакович, А.М. 2024. ОПЕРАТИВНЫЕ МЕТОДЫ ЛЕЧЕНИЯ ПЕРЕЛОМОВ ПЛЕЧЕВОЙ КОСТИ, ПРЕИМУЩЕСТВО БИОС . Научно-исследовательский журнал исследований травм и инвалидности . 3, 5 (май 2024 г.), 73–79.

Information ob autorax:

Juraev Ilkhom Gulomovich - Samarkandsky gosudarstvennyy meditsinsky University professor of traumatology and orthopedics, PhD . g. Samarkand , Uzbekistan . E - mail : Jurayev . inspiration @ list . ru , <https://orcid.org/0000-0003-1173-8572>

I Shkobilov Rustam Dzhankhurozovich - Samarkand branch of the Republican branch nauchnogo tsentra ekstrennyy meditsinskoy helper, occupational therapist, traumatologist , g. Samarkand , Uzbekistan . ishkabolovrustam746@gmail.com , <https://orcid.org/0009-0002-1738-5878>.

Information about the authors:

Juraev Ilham Gulomovich - Samarkand State Medical University, Department of Traumatology and Orthopedics, Associate Professor, Doctor of Philosophy. E - mail : Jurayev . inspiration @ list . ru , <https://orcid.org/0000-0003-1173-8572>

I Shkobilov Rustam Dzhankhurozovich- Samarkand branch of the Republican Scientific Center for emergency medical care with the department of traumatology . ishkabolovrustam746@gmail.com , <https://orcid.org/0009-0002-1738-5878>.

Istochniki finansirovaniya: Rabota ne imela spetsialnogo finansirovaniya.

Conflict of interests: Authors declare public and potential conflicts of interest, svyazannyx with publication status.

Vklad avtorov:

Juraev I.G— ideological concept work, text writing; editing status;

Ishkobilov R.Dz — collection and analysis of istochnikov literature, text writing.

Sources of funding: The work did not receive any specific funding.

Conflict of interest: The authors declare no explicit or potential conflicts of interest associated with the publication of this article.

Contribution of the authors:

Juraev IG- ideological concept of the work, writing the text; editing the article;

I shkobilov R. Dz - collection and analysis of literary sources, writing the text.