

# Morphometric parameters of the gastric mucosa under the influence of polypharmacy in white rats

Tashmamatov B.N., Dzumanova N.E.  
Samarkand State Medical University

## Resume

Polypharmacy is the simultaneous use of several drugs by one patient. As the population ages in developed countries, especially in the UK, the number of people with chronic diseases is increasing and there is increasing pressure on physicians to adhere to evidence-based guidelines for the management of chronic diseases .

**Keywords:** Polypharmacy, gastrointestinal tract, multiple diseases, clinical outcomes, lymphoid tissues

**Relevance** When the pesticide "Fastokin" was injected into the body of experimental animals, a change in the mucous membrane of the stomach, i.e. inflammation, was detected. The selection of the stomach for research is explained by the fact that many people suffer from various diseases in this organ: stomach inflammations and ulcers, and at the same time, the information about the fine structure of all the components that make up the walls of the stomach is not sufficiently revealed in the scientific literature [1,3,5,7,9,11,13]. Recent years have also seen the development of smartphone applications, such as My Medicine Passport, to improve communication between patients and health care providers, improve people's understanding of their condition and treatment, and track changes to a patient's medication. Polypharmacy is the simultaneous use of several drugs by one patient. As the population ages in the developed world, particularly the UK, the number of people with chronic diseases is increasing, and there is increasing pressure on doctors to adhere to evidence-based guidelines for the management of chronic diseases [2,4,6,8,10,12,14,16,18].

Despite the fact that many studies have been conducted in polypharmacy, information about the stomach, which is the central organ of the alimentary canal, is very scarce in the literature. In recent years, the issue of widespread use of non-steroidal anti-inflammatory drugs in order to mobilize the body's natural defenses, to form physiological and immunobiological reactions for the prevention and treatment of all types of baldness remains relevant [2,15,17,19,20, 21].

When studying the statistics of gastroenterological diseases in 2007-2017 in order to introduce pharmaceutical assistance in our country, one of the leading places among diseases of the digestive system was occupied by functional diseases of the stomach and intestines. Functional diseases of the alimentary tract accounted for 15-25% of the adult population, and the incidence of this disease increased by 22.4% in the last 10 years.

In foreign countries, the rate of death from side effects of drugs is one of the highest among the population deaths. Statistics show that drug polypharmacy with nonsteroidal anti-inflammatory drugs is common, and every doctor can unknowingly allow it. It allows to determine the reactive morphofunctional changes in the mucous membrane of the stomach wall observed as a result of factors that harm the human body and have a negative effect on it.

There are also cases where damage to the gastric mucosa caused by long-term use of anti-inflammatory drugs leads to the development of life-threatening situations and a decrease in the adaptive response. The study of the available scientific literature showed that the data on the morphological and morphometric changes of the structure of the stomach wall under the influence of polypharmacy have not been sufficiently studied, and this remains an open question until now. The connection of the study with the research plans of the higher educational institution where the dissertation was completed. In 2020-2022, the implementation of this dissertation work according to the plan and topic of scientific research work of the Bukhara State Medical Institute named after Abu Ali ibn Sina: "Morphometric changes of the gastric mucosa wall in the conditions of polypragmasia" is a new method for effective treatment and prevention of pre-disease pathological conditions. helps develop approaches.

**Purpose of scientific research:** The study was conducted on a total of 180 5-month-old adult white rats. According to the purpose of the study, all laboratory animals were divided into 5 groups. 5 different types of anti-inflammatory drugs were used in polypharmacy in different combinations. The histological material obtained from the cardiac, bottom, body and pyloric parts of the stomach of the experimental white male rats served as the subject of the study.

### **Material and methods**

Organometric, histomorphometric, microscopic and statistical methods were used as research methods. Organometric, histomorphometric and microscopic methods were used to study the morphogenesis structures (organ, tissue and cell) of the gastric mucosa and submucosa base of 5-month-old purebred male rats. In order to process the results obtained in our study, statistical methods were used. Structural changes in the organs of the digestive system have been proven to cause profound disturbances in the processes of growth and formation of the mucous membrane of the stomach and its glandular tissue, submucosa base, which is found to be accompanied by a decrease in the total thickness of the stomach wall; When using more than 3 types of anti-inflammatory drugs at the same time, the negative effects of polypharmacy increase significantly. The rate of formation of the structural and functional zones of the stomach wall, the activity of the cells in the mucous membrane, the change in the shape of the lymphocytes located at the base of the mucosa, and the decrease in the morphological parameters were analyzed; Using the methods of modern morphological research (organometric, histological, histomorphometric, statistical), new information was obtained directly about the morphological and morphometric parameters of the stomach wall. Changes identified at the tissue, cellular and intercellular levels are characterized by hypotrophic and hypoplastic changes in the structures of the gastric wall of the white male rat. The practical results of the research are as follows: The results of the conducted scientific research allow to determine the degree of morphometric changes in the stomach in polypharmacy, as well as to significantly deepen certain knowledge on the prevention, early detection and pathogenetic therapy of possible damage to all anatomical structures that make up the stomach wall in age categories.

The results of the research were implemented in the educational process of the departments of anatomy, clinical anatomy (CAD), histology, cytology and pharmacology of the Bukhara State Medical Institute.

Reliability of research results. In the process of research based on innovative, experimental, morphometric, laboratory and statistical methods of research. The above helps to determine the most characteristic regular changes of morphofunctional parameters, as well as to record the formation and genesis of pathological disorders in the stomach walls of rats in polypharmacy. In addition, the reliability of the results of scientific research is based on the confirmation by the competent authorities of the data and conclusions obtained from the comparative analysis of the results of the work with the information presented in local and foreign sources. Scientific and practical significance of research results. According to the scientific significance of the results obtained from the research on the structural disorders of the gastric wall morphological parameters, it is manifested in the rational approach to the determination of the complex defense mechanism of the organism, which occurs as a result of the influence of various pathogenic factors. The scientific and practical significance of the research results is based on the high level of explanation of the structural and functional mechanisms of changes in the stomach wall observed in the norm and the effect of polypharmacy. This, in turn, helps to determine the most critical periods that are necessary for the implementation of measures for the prevention of stomach diseases.

The results of the conducted scientific research are very important in the field of applied medicine, their fundamental-theoretical and practical importance. This is an experimental basis for the development of scientific methods of prevention, prevention and pathogenetic therapy of possible damage to other layers of the organ wall. The importance and effectiveness of morphometric study of hidden pathomorphological changes occurring in all layers of the stomach wall in polypharmacy was justified.

### **Result and discussion**

This work was carried out in the research laboratory of the Bukhara State Medical Institute named after Abu Ali Ibn Sina during 2020-2022. A total of 180 purebred male rats were selected as experimental animals and

kept in quarantine for 7 days. From the day of transfer to vivarium conditions, a 3-times-a-day feeding regimen was established. In order to study the effects of polypharmacy in experimental laboratory animals, a group of anti-inflammatory drugs were used: Aspirin (SAQDV - salicylic acid derivatives), Paracetamol (SAQDV - anilide derivatives), Ibuprofen (SAQDV - propionic acid derivatives), Dexamethasone (synthetic hydrocorticosteroid), Plaquinil sulfate (anti-inflammatory and antimalarial with an antimalarial effect). Experimental animals were divided into 5 groups (n = 180): I - control group (n = 25); II - group - rats that received 2 types of anti-inflammatory drugs, paracetamol 15 mg / kg, aspirin 5 mg / kg (n = 45); III- group - rats that received 3 types of anti-inflammatory drugs, paracetamol 15 mg / kg, aspirin 5 mg / kg, ibuprofen 6 mg / kg (n = 35); Group IV - rats 4 types of anti-inflammatory drugs, paracetamol 15 mg/kg, aspirin 5 mg/kg, ibuprofen 6 mg/kg, dexamethasone 0.1 mg/kg. (n = 35); Group V - rats receiving 5 types of anti-inflammatory drugs, paracetamol 15 mg/kg, aspirin 5 mg/kg, ibuprofen 6 mg/kg, dexamethasone 0.1 mg/kg, hydroxychloroquine sulfate 6.5 mg/kg (n = 40). The doses of the used drugs were calculated empirically and were injected into the stomach in the form of a solution through a metal probe every day for 10 days. White rats in the control group were injected with 0.5 ml of distilled water through a metal tube for 10 days from 141 days.

After opening the abdomen, the macroanatomy, skeletoscopy and syntopy of the stomach were studied. After the study of the macroanatomy of the stomach was completed, the surrounding tissues were dissected. At the next stage, the weight of the rats was measured using a scale, and the anatomical parameters of the stomach removed using a barbell were measured. Organ wall components such as mucosa, folds, pits between folds, submucosa base, glandular tissue, muscle, and total thickness of the stomach wall were measured. For morphological and morphometric studies, the removed stomach was fixed in Buen's solution, and after the necessary process, the material was embedded in paraffin according to generally accepted rules. After that, 6-7  $\mu$ m thick transverse histological sections were prepared by bleaching the pieces from the cardial, bottom, body and pyloric parts of the stomach in high concentration alcohol. After deparaffinization, the sections were stained with hematoxylin-eosin and Van-Gison method. Morphometric studies and measurements of tissues taken from stomach sections were performed under a NLCD-307B microscope. The following indicators were determined when the topographic-anatomical and skeletoscopic data of the stomach of a white rat were studied. In non-laboratory white rats, the upper or upper back wall of the stomach touches the jejunum and ileal loops on the right side, and the left adrenal gland and the left kidney on the left side. Stomach closes the upper 2/3 of the lower surface of the adrenal gland of the left kidney and close to the upper end of the left kidney, i.e. the front end. The left side of the stomach is rounded, it is located mainly under the diaphragm, and on the left side it is located touching the spleen. The right side of the stomach narrows and connects from the last part to the beginning of the duodenum. Adjacent to the right side of the stomach is the duodenum, which is external to it, while the rest of the stomach lies under the visceral surface of the liver. The above condition means that it has reached the right border of the liver gate (fig. 1).

Note: the number of rats that died during the experiment is shown in parentheses In the process of using experiments on laboratory rats, our actions were in accordance with the requirements of the document "Rules for conducting work with experimental animals" (No. 18 dated 16.01.2018) of the Ethical Committee of the Bukhara State Medical Institute named after Abu Ali ibn Sina, in addition, in 1964, the International Medical The declaration adopted by the association in Helsinki and completed in 1975, 1983, 1989, 1996, 2000, 2002, 2004, 2008, 2013 was strictly observed. The weight of the experimental rats was measured in the morning at the specified times. After that, the experimental rats were quickly decapitated by ether anesthesia on an empty stomach, and they were removed from the experiment.

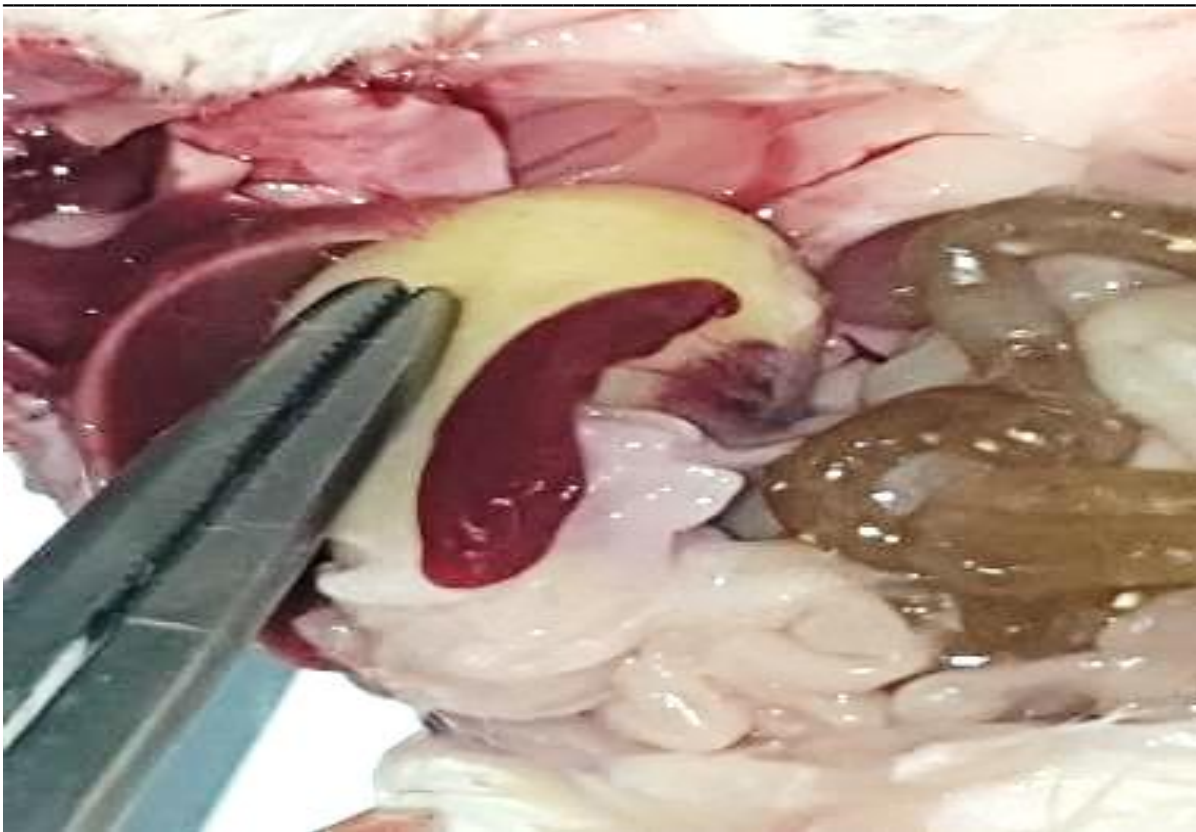


Figure 1. Topography-anatomy of five-month-old white rat stomach.

A small curvature of the stomach wall is located transversely in its front part, and after the organ is full, it is observed to increase in size. In the lesser curvature of the stomach, there is a junction of the esophagus with the stomach, and it is connected to a specific topographical-anatomical area, that is, in the middle part of the lesser curvature of the stomach (figure 1). The greater curvature of the stomach is located on the back of the organ, and is often located transversely. There are several lines from the abdominal organs of white rats to the stomach, and they are as follows: Stomach- splenic line: - from the spleen to the great curvature of the stomach; Diaphragm-stomach line: - from the diaphragm to the left half of the greater curvature of the stomach; Liver-stomach section: - from the area of the liver gate to the small curvature of the stomach; Gastrointestinal tract: - starts from the great curvature of the stomach and continues to the transverse colon. Five-month-old purebred laboratory rats have fully formed stomachs. When the five-month-old rats in the experiment were examined macroscopically, the following data were obtained:

The body weight of five-month-old laboratory animals varied from 189-258 g, and the average was  $244.6 \pm 6.3$  g. The total length of the white rat stomach in the control group was 33-35 mm, with an average of  $34.62 \pm 0.18$  mm. The width of the member varied from 13 to 15 mm and averaged  $13.81 \pm 0.18$  mm. The thickness of the studied organ varied from 12 to 15 mm, and the average was  $13.69 \pm 0.32$  mm. The length of the large curvature is around 37 - 38 mm, on average  $-37.43 \pm 0.10$  mm. The length of the small curvature was 14 - 15 mm, the average was equal to  $-14.65 \pm 0.10$  mm. Group V. Comparative description (%) of the morphological parameters of the components of the stomach wall of white male rats in the period of 5 months, with the parameters of the control group.

The following results were obtained when the components of the gastric wall of experimental group V rats were compared with 5-month-old white rats in the control group. The thickness of the gastric wall of the cardiac part of the mucous layer is 8.4%, the height of the fold is 8.8%, the cavity between the folds is 6.08%, the submucosa base is 10.5%, the thickness of the total muscle layer is 0.21%, the gland it can be seen that the tissue is reduced by 37.0%, and the total thickness of the stomach wall is reduced by 2.21%. At the bottom of the organ wall, these indicators changed as follows. The height of the total mucous layer increased by 7.6%, the height of its fold increased by 10.01%, the indentation between the

folds increased by 8.52%, the submucous base increased by 17.8%, the thickness of the general muscle layer increased by 0.29%, glandular tissue increased by 29, 7%, and the total thickness of the stomach wall decreased by 3.89%, the height of the mucous layer in the body of the stomach decreased by 6.52%, the height of the fold by 10.7%, the cavity between the folds by 16.2%, the submucosa base by 16,7%, the thickness of the total muscle layer decreases by 0.61%, the glandular tissue decreases by 34.4%, and the total thickness of the stomach wall decreases by 3.01%. In the pyloric part of the medial wall, the height of the mucous layer is 6.2%, the height of the fold is 9.84%, the indentation between the folds is 15.1%, the submucous base is 15.9%, the thickness of the general muscle layer is 1.6%, the gland it was found that the tissue decreased by 32.2%, and the total thickness of the stomach wall decreased by 2% (table 2).

### Conclusion

Different levels of morphological changes occur under the influence of different amounts of drugs. According to the obtained data, the overall thickness of the stomach wall significantly decreased in groups IV-V due to the decrease in the size of the gastric mucosa and the mucosal base after the effect of drugs. These changes were 1.60% in the cardiac part, 3.27% in the gastric fundus, 3.33% in the body and 3.65% in the pyloric part of laboratory animals of the IV group, and 2.21% in the cardiac part of the organ in the laboratory animals of the V group. %, changed to 3.89% in the base, 3.0% in the body of the stomach and 5.2% in the pyloric part. When the adverse effects of polypharmacy with anti-inflammatory drugs were compared with the rats of the experimental control group and the rest of the groups, when the measurements of all the morphometric parameters obtained were viewed in the increasing order of the group, it was observed that the negative effects significantly increased in accordance with it and parallel to it.

The adverse effects of polypharmacy of anti-inflammatory drugs in the experimental group of rats in the stomach wall, mucosal base and glandular tissue in the experimental group were corrected in the V-group compared to the I-control group. In this case, in the cardiac part of the organ wall of group V, the height of the mucous layer of the gastric wall is 8.4%, the mucosal base is 10.5%, and the glandular tissue is 37.0%, the mucosal layer is 7.60% at the bottom of the stomach, 17.8% based on the mucosa., and in the gland tissue by 29.7%, the height of the mucous membrane in the organ body by 6.52%, the base of the mucosa by 16.7% and in the gland tissue by 34.4%, the height of the mucous membrane in the pyloric area of the stomach by 6.2%, the mucosa it was found that it did not decrease by 15.9% in the base and by 32.2% in the gland tissue.

### List End Referances:

1. Dzhumanova N.E. and others. CHANGES IN MORPHOLOGICAL AND MORPHOMETRIC PARAMETERS OF THE GASTRIC WALL DURING POLYPRAGM MASS WITH THE USE OF ANTI-INFLAMMATORY DRUGS // World Bulletin of Public Health. – 2023. – T. 22. – P. 160-164..
2. Norbekovich T. B., Eshmamatovna D. N. CHANGES IN THE MORPHOLOGICAL AND MORPHOMETRIC PARAMETERS OF THE GASTRIC WALL IN POLYPRAGM MASS WITH ANTI-INFLAMMATORY DRUGS // EDUCATION, SCIENCE AND INNOVATION IDEAS IN THE WORLD. – 2024. – T. 45. – No. 4. – pp. 121-127.
3. Toshmamatov B.N. CHANGES IN MORPHOLOGICAL PARAMETERS OF THE STOMACH MUCOSA AND THE BASICS OF THE MUCOUS IMAGE OF THE STOMACH OF WHITE RATS UNDER POLYPRAGM // Proceedings of the international conference on scientific research in the field of natural and social sciences. – 2024. – T. 3. – No. 5. – pp. 162-171.
4. Toshmamatov B. N., Dzhumanova N. E. YALLIGLANISHGA KARSHI DORI VOSITALARI BILAN POLYPRAGMAZYADA MEDA DEVELOPMENT MORFOLOGIK VA MORPHOMETRIC PARAMETRLARIDAGI OZGARISHLARI //TADQIQOTLAR. UZ. – 2024. – T. 38. – No. 1. – pp. 248-257.