

# Early Lateral Closing Wedge Surgical Correction of Cubitus Varus Deformity Complicating Supracondylar Humeral Fracture in Children

Dr. Yousif Awad Jaber Almarawee  
M.B.CH.B./H.D./ (Orthopedic)  
Iraqi Ministry of Health, The Gar Health  
Al-Shattra Hospital  
The Gar, Iraq.  
Yusufawad73@gmail.com

## Abstract:

**Background :** Cubitus varus deformity complicating supracondylar fracture of humerus in children usually implies a malunion from inappropriate treatment of the fracture . The resulting deformity can be solved only by osteotomy ,since the deformity once established it will not correct by remodeling . A lot of controversy is still present regarding the best age of the child to perform the corrective osteotomy . Cosmetic appearance is the most common indication for osteotomy . **Methods :** Between April 2010 and November 2011 a prospective study was conducted on seven children with established cubitus varus deformity complicating supracondylar fracture of the humerus .Cubitus varus in these children was the result of failed manipulation and casting of the supracondylar fracture in 5 children (71%) or open reduction and Krischnner wires fixation in the remaining 2 (29%) .Clinical measurement of the carrying angle and radiographic assessment of Baumann' s angle on normal and deformed sides were used to assess the degree of the varus deformity in all children .All children were treated surgically by a lateral closing wedge osteotomy of distal humerus, through posterior triceps splitting approach, followed by internal fixation using 2 cortical screws and a figure of 8 wire loop (French' s method) .The average age at time of surgery was 7 years (range 3-10 years) .There were 6 boys (86%) and one girl (14%) . Time interval between the supracondylar fracture and corrective osteotomy was 3-12 months (average 10 months) .**Results :** All children were followed up for 6-9 months .All children regained satisfactory cosmetic results after correction with an average of 81° postoperative Baumann' s angle (range 79°-84°) and preoperatively the average was 95° (range 105°-90°) .The measured carrying angle postoperatively ranged from 6°-13° (average 9°) and preoperatively the average was -15° (range -22° to -10°) .No operative complications or flexion contracture occurred in this study group .The average maximum elbow flexion postoperatively ranged from 132°- 139° (average 135°) and preoperatively ranged from 140°-133° (average 137°) . Significant lateral condyle prominence was not recorded in this study .**Conclusion :** Early lateral closing wedge osteotomy to correct posttraumatic cubitus varus as soon as the elbow can be fully extended by the child is reasonable for poor compliance patients.

**Aims of study** To evaluate the lateral closing wedge osteotomy and short term results of early corrective osteotomy in the treatment of cubitus varus deformity complicating supracondylar fracture of humerus in children .

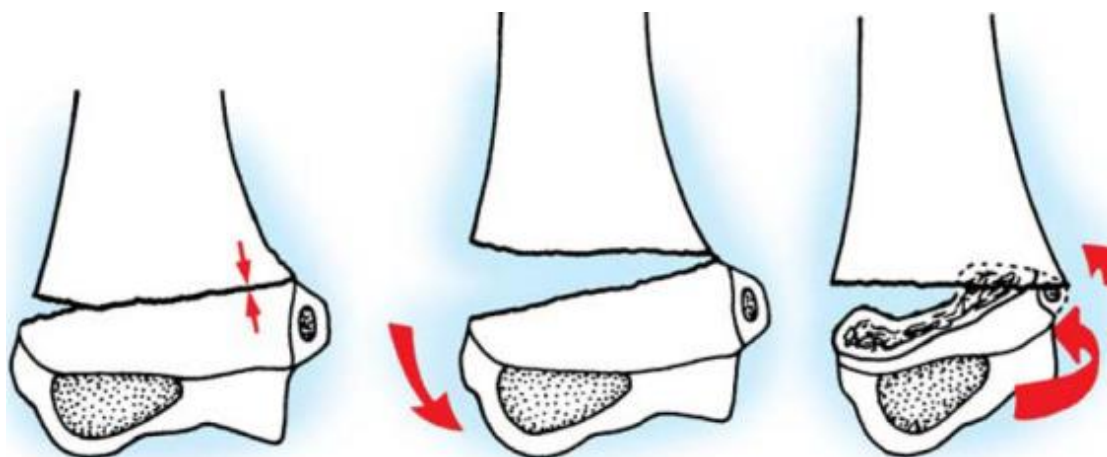
**Key Words :** supracondylar, fracture , humerus, children, lateral closing.

## Introduction:

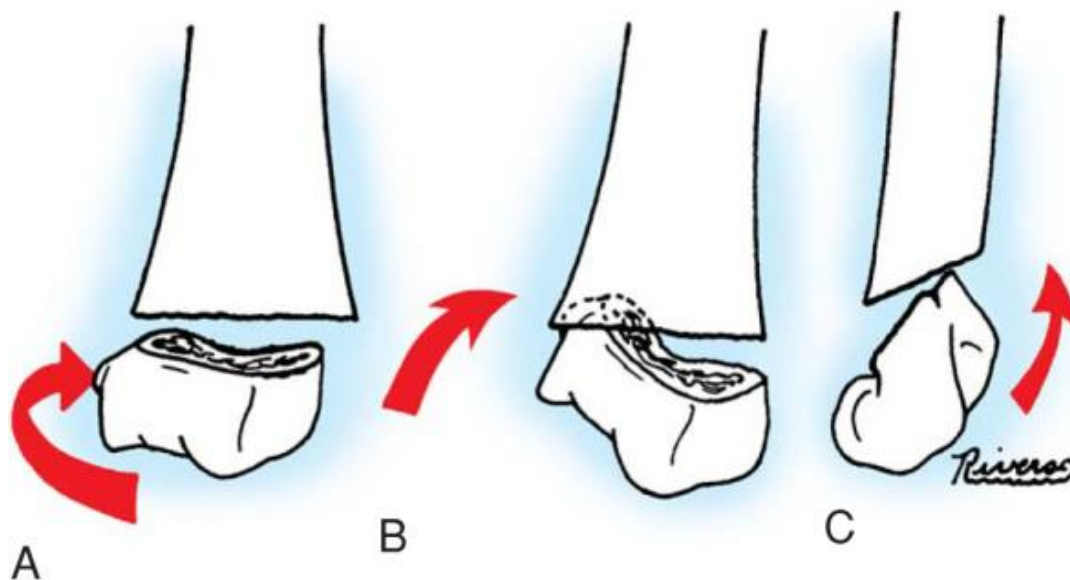
Cubitus varus is the most common late complication following supracondylar fracture of humerus in children<sup>(1-7)</sup> . The reported incidence (9% to 58%) varies with the type of treatment more in conservative than in surgical treatment of original supracondylar humeral fracture in children <sup>(3,5)</sup> . Visible to naked eye ,cubitus varus is usually not diagnosed until after healing of the prior fracture, as the arm must be in full extension, not flexion, for the deformity to be noticed . Certain grades of the fracture ,certain radiographic appearances will guess which fracture is liable to be complicated by cubitus varus even before the deformity

is clinically evident<sup>(8)</sup>. Immediate and late causes of cubitus varus deformity are medial angulation, medial rotation, overgrowth of lateral condyle and osteonecrosis or delayed growth of medial condyle. The medial angulation is the major determinant for the deformity, while medial rotation contributes to it<sup>(1)</sup>. Cubitus varus exists in 3 planes; horizontal, coronal and sagittal ones. Plain radiography can measure only 2 planes (coronal and sagittal). To measure the internal rotation, one would have to depend upon computed tomography, which is quite expensive and have more radiation hazards on growing child<sup>(2)</sup>. This is a permanent deformity and will not improve with growth.<sup>(9)</sup>

As noted by Wilkins and others, horizontal rotation predisposes to coronal tilting, and a combination of horizontal rotation, coronal tilting, and posterior displacement can result in a three-dimensional deformity of cubitus varus<sup>(10)</sup>. (figures 1 and 2)



**Figure (1)<sup>(10)</sup>: A B C**  
**Mechanism of coronal tilting. A. Impaction of fracture medially. B. Tilting of fragment medially. C. Horizontal rotation.**

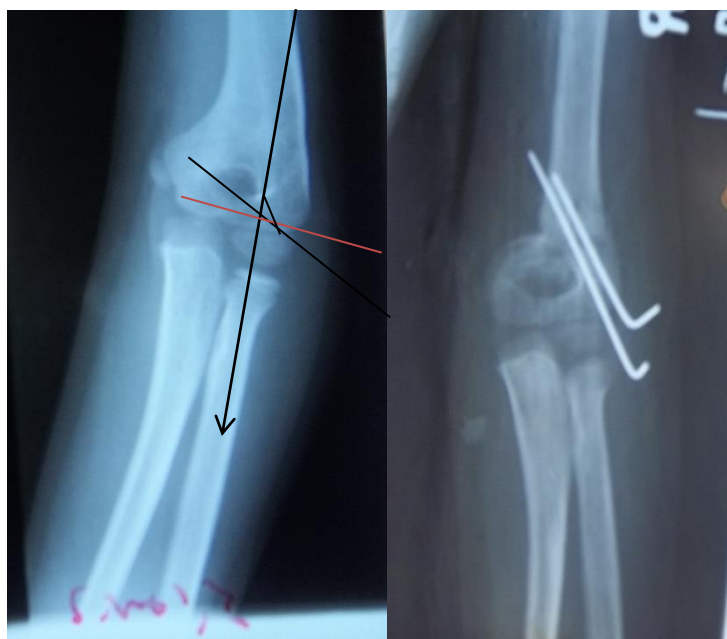


**Figure (2) (10) : Three static components that combine to produce cubitus varus.( A) Horizontal rotation. (B) Coronal tilting. (C)Anterior angulation .**

Growth disturbance as a cause of cubitus varus has largely been refuted. The fracture is extra physeal and so physeal damage should not be blamed for the deformity; usually its faulty reduction which is responsible<sup>(9)</sup>.

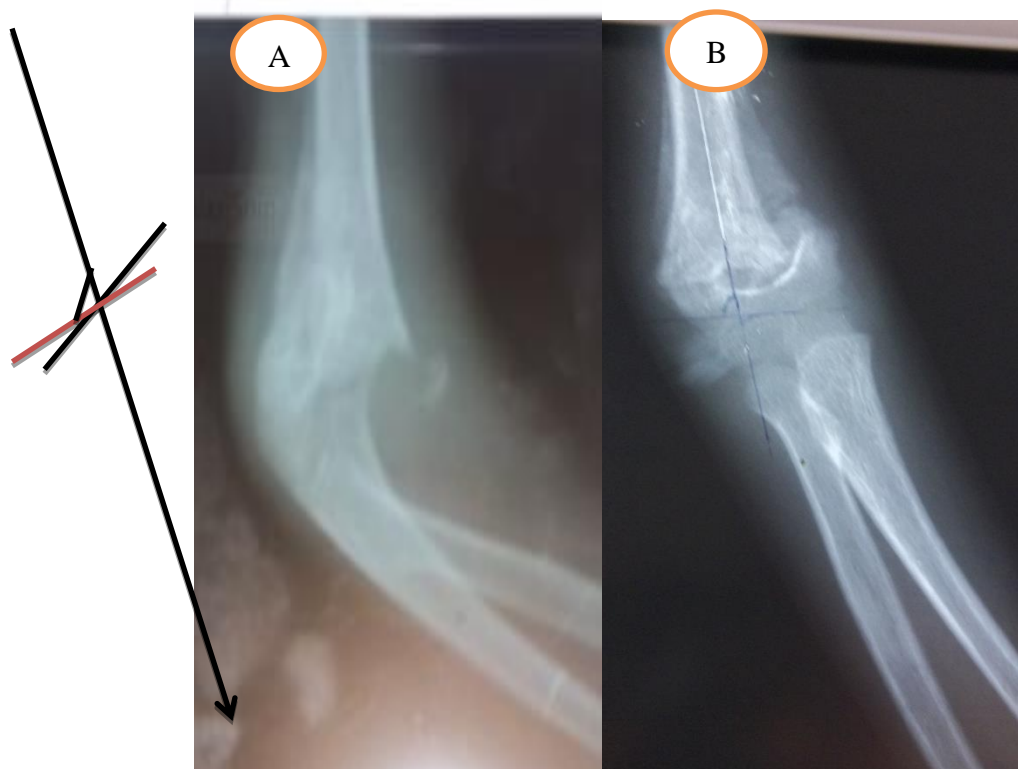
Despite a remarkable potential for remodeling in children, an established varus deformity does not improve with time<sup>(11)</sup>.

Failure to reduce the supracondylar fracture anatomically or loss of reduction both with the conservative and operative methods of treatment is the main cause of cubitus varus (as shown in figure 3 and 4 )



B A

**Figure(3). A. The fracture has been reduced and pinned in varus. Note the shortening of the medial column . B. Varus malalignment after removal of Kirschner wires. (photographed by the researcher).**



**Figure(4) . Varus malunion following closed reduction : anteroposterior (A) and lateral (B) .(photographed by the researcher).**

Cosmetic appearance is the most common indication for surgery. Many authors now agree that surgery should be done as early as deformity becomes established<sup>(10,12)</sup>. Several techniques for corrective osteotomy of the distal humerus have been described, including a lateral closing osteotomy, a rotational dome procedure, an oblique medial opening osteotomy and a step-cut lateral closing osteotomy, with various devices being used for internal and external fixation<sup>(1,5,7)</sup>.

### **Relevant Anatomy :**

In children ,the supracondylar region of the humerus is composed of an area of thin, weak bone located in distal humerus.It may be thought of as a triangle. The base of the triangle is articular surface consisting of the trochlea, which articulates with the ulna and the capitellum which articulates with the radius. The two sides of the triangle or the medial and lateral columns of the distal humerus which may be thought of as a strong columns of predominantly cortical bone supporting any forces that occur across the elbow<sup>(13)</sup> .

The medial and lateral columns of the distal part of the humerus are connected by a thin segment of bone between the olecranon fossa posteriorly and the coronoid fossa anteriorly, resulting in a high risk of fracture to this area<sup>(13)</sup> .

Supracondylar humeral fracture in children are divided into extension and flexion types. Extension type fractures account for approximately 95% of supracondylar humeral fractures and are usually due to a fall onto the outstretched hand with the elbow in full extension. With this mechanism , the olecranon engages the olecranon fossa and acts as a fulcrum and causing the fracture. The anterior aspect of the capsule simultaneously provides a tensile force on the distal part of the humerus proximal to its insertion. The fracture line typically propagates transversely across the distal humerus through the center of the olecranon fossa<sup>(13)</sup> . Depending on the severity of the fracture , posterior displacement of the distal fragment and anterior displacement of the proximal fragment may occur. It should be noted that the long axis of the extended forearm lies at an angle to the long axis of the arm. This angle, which opens laterally, is called the *carrying angle* and is about 170°or (10° valgus) in the male and 167°or (13° valgus) in the female<sup>(13)</sup>. The angle disappears when the elbow joint is fully flexed<sup>(9)</sup>.

### **Important Relations to the elbow joint :**

Anteriorly: The brachialis, the tendon of the biceps, the median nerve, and the brachial artery.

Posteriorly: The triceps muscle, a small bursa intervening.

Medially: The ulnar nerve passes behind the medial epicondyle and crosses the medial ligament of the joint.

Laterally: The common extensor tendon and the supinator<sup>(13)</sup>.

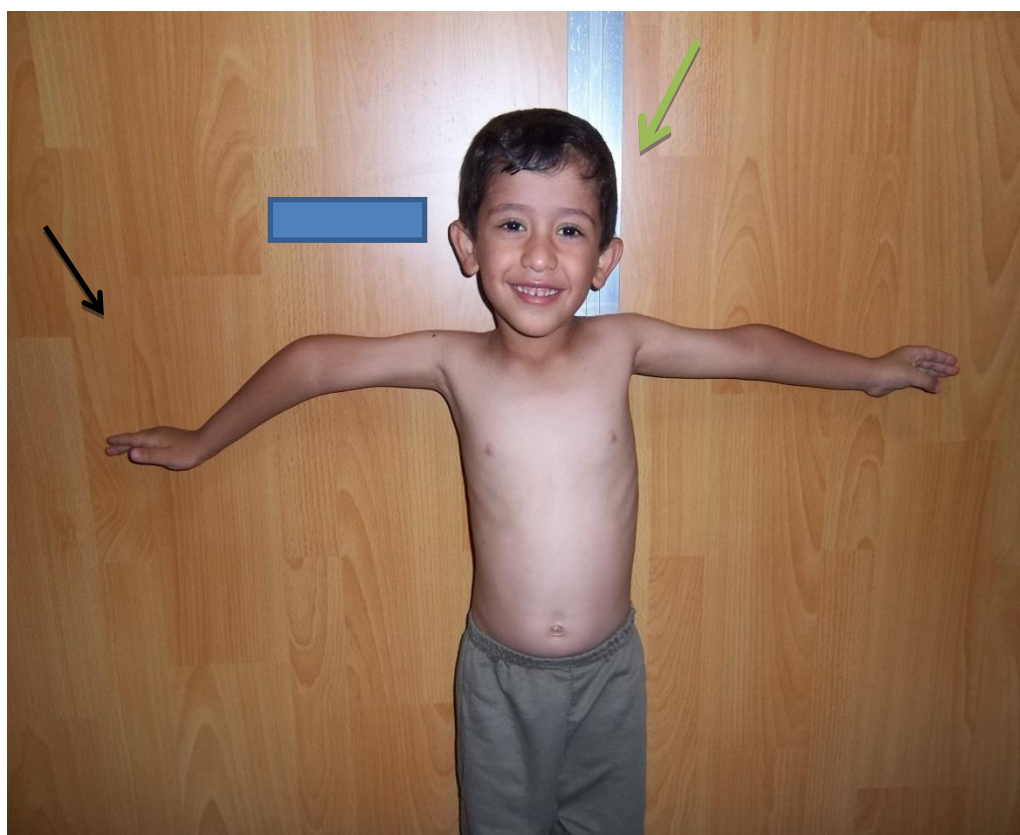
### **Clinical feature of cubitus varus:**

In varus deformity of the elbow joint ( GUN STOCK deformity ) there's full range of elbow movement , no pain or stiffness no neurological sign or symptoms<sup>(10)</sup> . Varus deformity may be more frequently reported simply because it is more cosmetically noticeable as shown in figures (5 and 6) .

Flexion, extension, pronation and supination of the elbow and forearm are usually normal. When the elbow is viewed from behind, it shows that the olecranon is prominent and slightly displaced towards the inner side, flattening of the inner side of the elbow, and fullness of the outer side on-flexion at a right angle with apparent enlargement of the external condyle below and behind. On palpation, the external condyle appears to be thickened and lowered; the head of the radius rotates against an apparently normal capitellum; the internal epicondyle is less prominent than normal<sup>(14)</sup> .

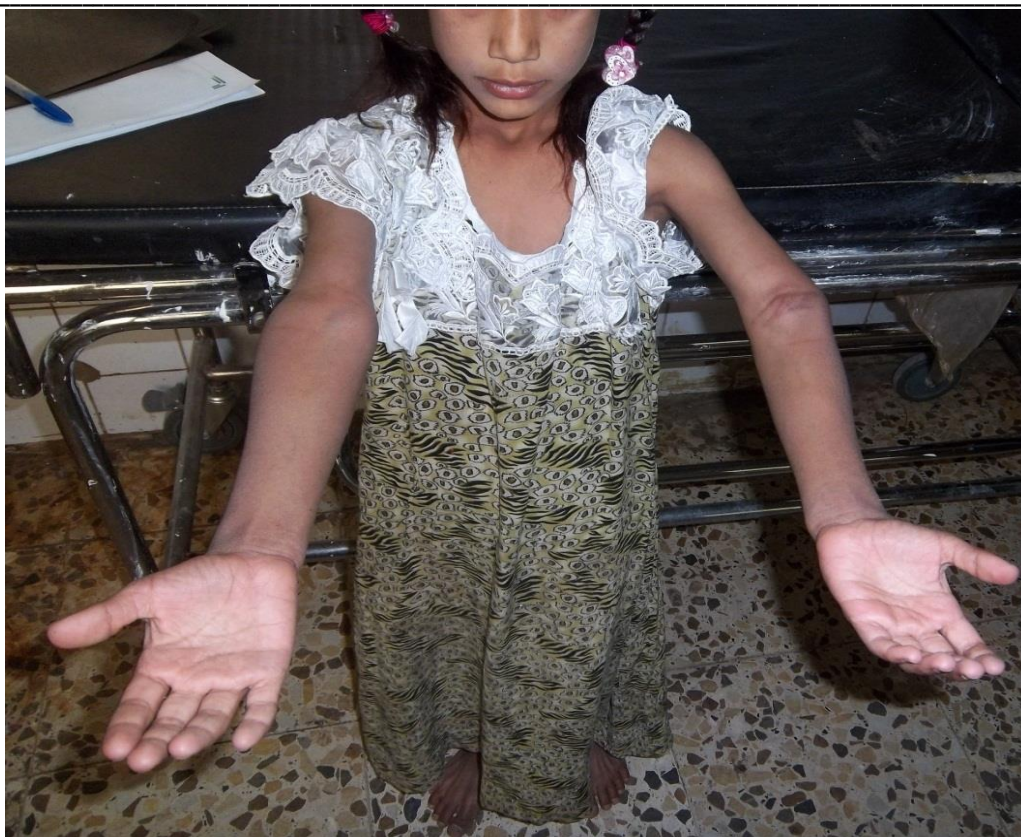

Figure (5) .Left sided cubitus varus following conservative treatment. (photographed by the researcher )

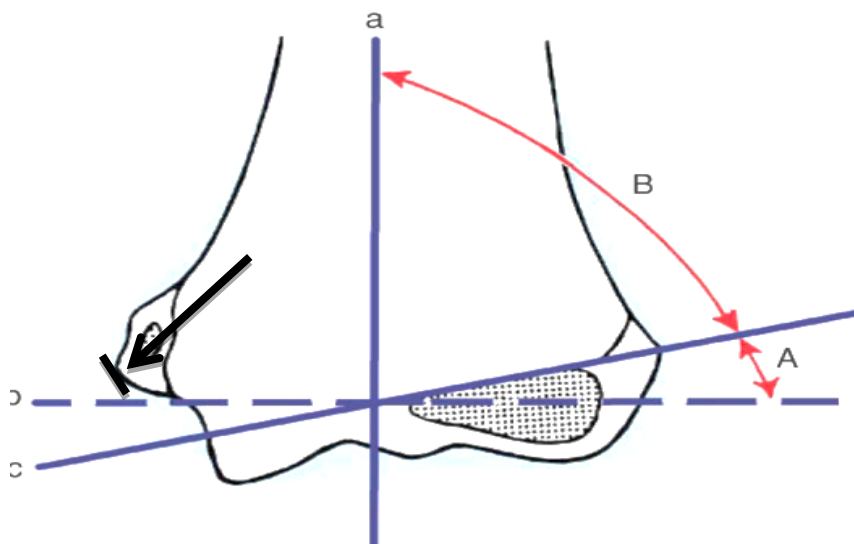


Figure(6).Right sided cubitus varus following surgery. ( photographed by the researcher)

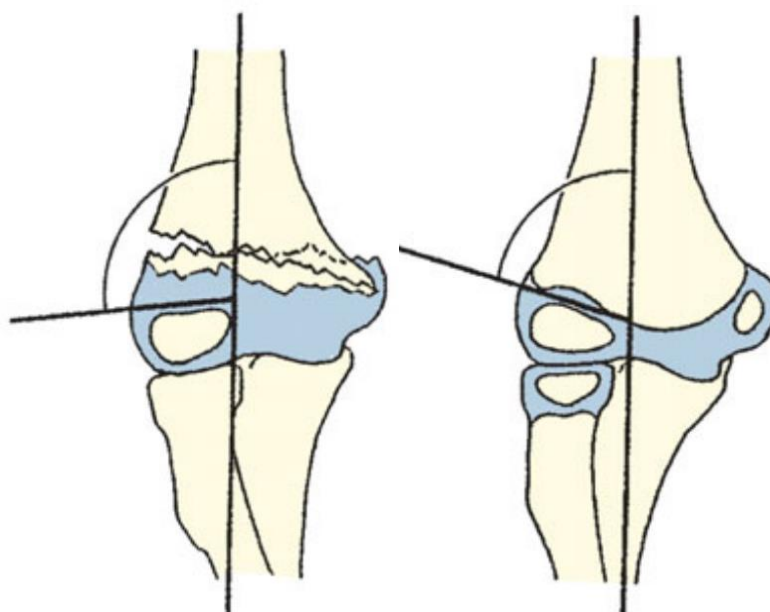
**Radiological features of cubitus varus :**

Anteroposterior radiographs of the elbow joint is the most important view to assess the degree of cubitus varus by measuring various angles including :

**a-The Baumann's angle** or humeral capitellar angle, is the angle between the long axis of the humeral shaft and the physal line of the lateral condyle (figures 7 and 8) . The normal range for this angle is about  $64-81^{\circ(10)}$  . The measurement of Baumann's angle is useful in assessing the degree of medial angulation . The increase in the Baumann's angle is a sign that a fracture is in varus angulation and may be seen with subtle comminution of the medial column <sup>(9)</sup> .



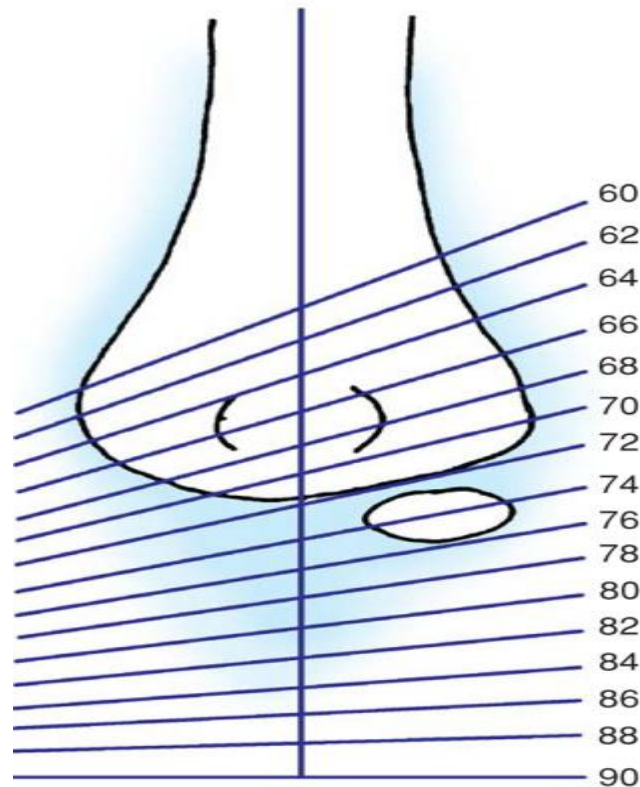
**Fig.(7) <sup>(10)</sup> Baumann's angle . a, Midline diaphysis of humeral shaft. b, Line perpendicular to midline. c, Line through physis of lateral condyle. Angle A is original Baumann angle. Angle B is more commonly used currently.**



**Normal (non fracture side) . B. Abnormal (fracture side) . A figure (8).<sup>(9)</sup> measurement of Baumann's angle.**

Important points to be considered in measurements of Baumann's angle:  
1-Normally  $64^{\circ} - 81^{\circ(10)}$

- 2-Comparison with other elbow is a must.
- 3-Change in x- ray of 20°cephalad or caudad make it invalid.
- 4-Using of overlay grid of angle make it easy to measure the angle<sup>(10)</sup> .(figure 9)

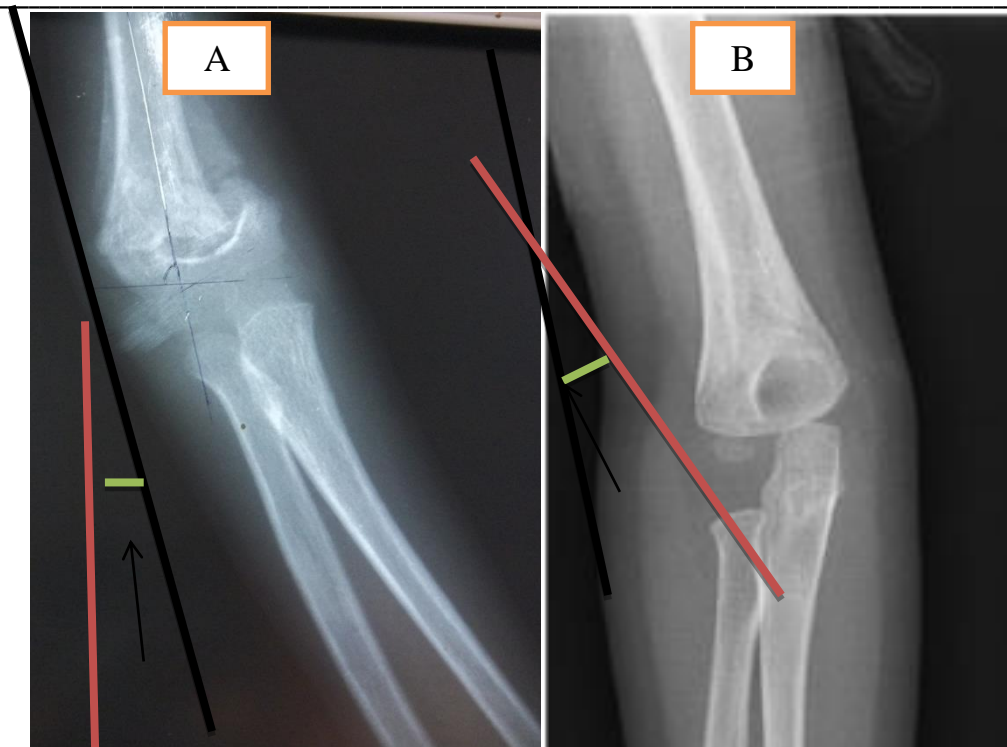


**Figure(9)<sup>(10)</sup> Measurement of Bauman's' angle with overlay grid of angles**

In normal children the Baumann angle is the same in both elbows and it has been suggested that a comparison between the injured and normal sides could be used to assess the accuracy of reduction (Dodge 1972)<sup>(15)</sup> . A reliable method of radiological assessment has been described by Reinaerts and Cheriex (1979)<sup>(16)</sup> this involves placing the film on the posterior aspect of the upper arm parallel to the humeral shaft and perpendicular to the x-ray beam. The beam is then directed at the distal humerus within a 10° arc, either medially or laterally, of the forearm. There is no significant distortion of the Baumann angle within these limits.

**b- Humeral – ulnar –wrist angle**

Oppenheim et al.<sup>(17)</sup> and others suggested that *the humeral-ulnar-wrist angle is the most consistent and accurate method of approximating the true carrying angle*. As shown in figure (10)



Figure(10). Humeral-ulnar-wrist angle .(A)Normal angle (B)Cubitus varus (photographed by the researcher).

#### Treatment:

Unfortunately, because of the limited growth and the fact that deformity is most commonly perpendicular to the plane of motion, there is little potential for angular malunion of the distal humerus to remodel. Mild degrees of malunion can be treated by simple reassurance. However, if the deformity is severe, cosmetic concerns or, less commonly, functional limitations may warrant surgical reconstruction<sup>(18)</sup>. Davids et al<sup>(19)</sup> also believed that a post traumatic cubitus varus deformity should not be considered only as a cosmetic deformity because the varus malalignment of the elbow in such injuries might easily predispose child to subsequent lateral condylar fractures. Like any surgical procedure, the family should be warned about the possible postoperative complication that might be encountered<sup>(18)</sup>.

Recently, some authors have recommended early correction of the deformity rather than waiting until after skeletal maturity, because the deformity is not progressive and does not improve with remodeling. Those authors found better long-term results in the pre pubertal group than in the post pubertal group<sup>(5,20,21)</sup>.

#### Techniques for corrective osteotomy :

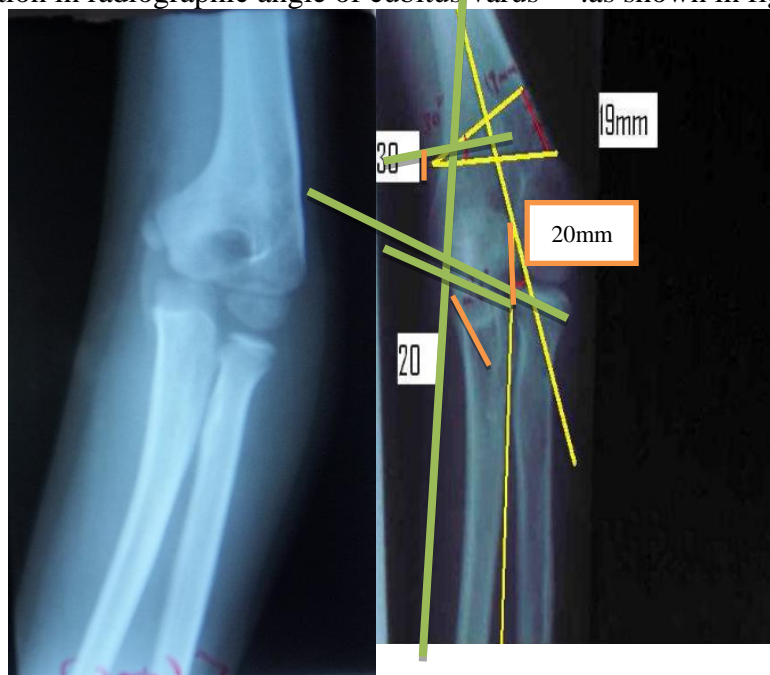Various techniques for corrective osteotomy for cubitus varus have been described, including :

- 1. A lateral closing wedge osteotomy:** is the easiest, the safest, and inherently the most stable osteotomy<sup>(10)</sup>
- 2. A medial opening wedge osteotomy with a bone graft:** The disadvantages of this osteotomy are that it gains length, which is not a problem in the upper extremity, and it creates a certain amount of inherent instability and the need for bone graft. Lengthening the medial aspect of the humerus also can stretch and damage the ulnar nerve, unless it is transposed anteriorly<sup>(10)</sup>. The technique is demanding and is not reproducible.
- 3. An oblique osteotomy with derotation:** can be beneficial, but the derotation is probably unnecessary<sup>(10)</sup>.
- 4. Three-dimensional osteotomy for correction of cubitus varus deformity:** Medial and posterior tilt are corrected. After osteotomy, distal fragment is compacted with proximal fragment by adding external rotation using wedge of humeral cortex. Bone graft is added if necessary. It's very difficult procedure and need careful preoperative planning and special attention to surgical details and are used mainly in older children and young adults<sup>(10)</sup>.
- 5. Dome osteotomy :** In 1982, a dome osteotomy was introduced to overcome several reported complications of lateral closing-wedge osteotomy, when used in adult<sup>(22)</sup>.



### For removal of wedge:

In lateral closing wedge osteotomy an amount of bone to be removed is calculated pre-operatively on the x-ray tracings of the normal and deformed limbs. Each one millimeter in the length of the wedge is equal to one degree of correction in radiographic angle of cubitus varus<sup>(6)</sup> as shown in figure (11).



Figure(11). Preoperative calculation of wedge size using 2 different methods . A. humeral-ulnar-wrist angle of (-20°) varus and the (19mm) planned width of supracondylar wedge to produce correction of the varus deformity<sup>(6)</sup> .B. the Baumann's angle of 100° varus and the (20mm) planned width of supracondylar wedge to produce correction of the varus deformity(photographed by the researcher).

#### Methods of fixation:

Different modalities of fixation devices can be utilized to hold the corrected position after osteotomy including :

- 1- Preset Kirschner wires .
- 2- Two screws and a wire attached between them .
- 3- Plate and screws fixation.
- 4- Compression fixation by screw across the osteotomy.
- 5- Staples.
- 6-External fixation .
- 7-Some authors had used no fixation apart from plaster of Paris .

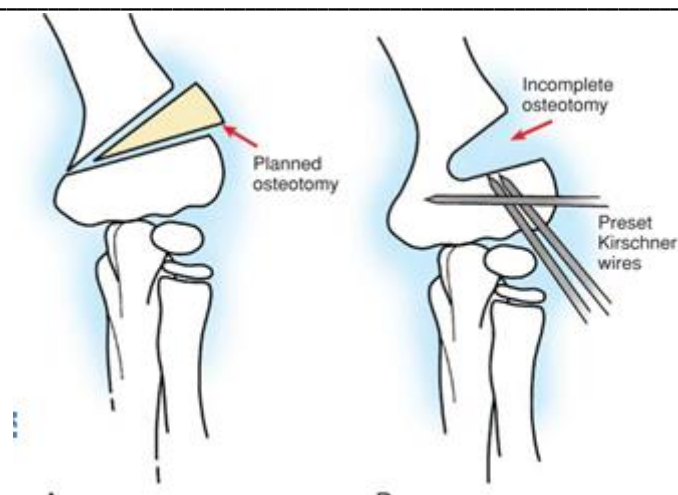
In the literature, Kirschner wire fixation is the most prevalent method of holding the osteotomy (10) .

#### Varieties of lateral closing wedge osteotomy :

The primary difference in the types of lateral closing wedge osteotomy are the methods of fixation .

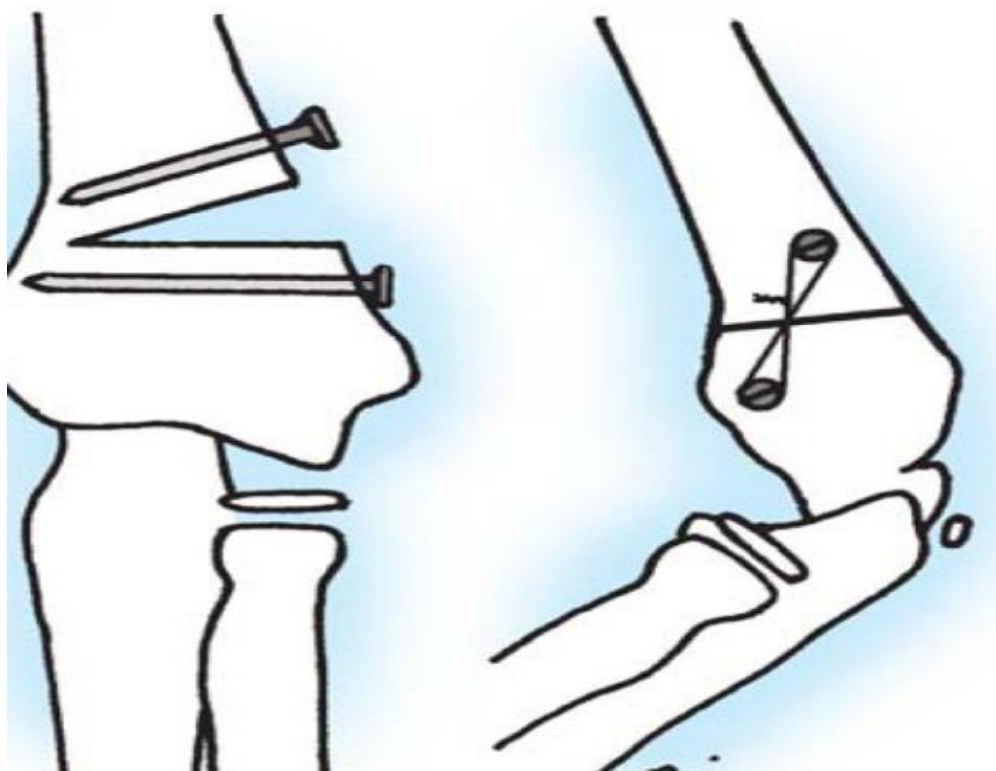
**1-Uniplanar supracondylar closing wedge humeral osteotomy fixed either by preset Kirschner wires or French method .**

a- Preset Kirschner wires is simple with good correction and minimal complications. Complications of this method of fixation are loosening of the fixation with recurrent deformity has been noted, as well as pin track infections, osteomyelitis, skin slough, nerve palsy, and rarely aneurysm of the brachial artery<sup>(10, 23)</sup> .(figure 12)



Figure(12).<sup>(10)</sup>

b- French method <sup>(10)</sup> (figure 13) two parallel screws that are attached by a single figure-of-eight wire that is tightened for fixation.

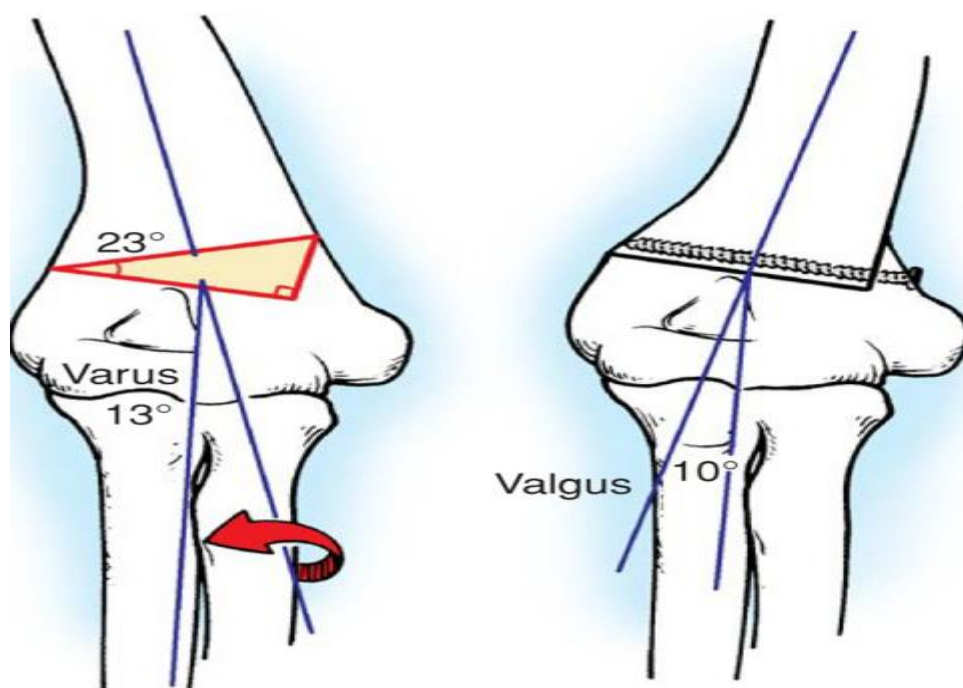


Figure(13)French osteotomy<sup>(10)</sup>

c- French, Modified by Bellmore et al.<sup>(10)</sup>

Same procedure a part from chosen posterolateral incision to expose lower humerus .

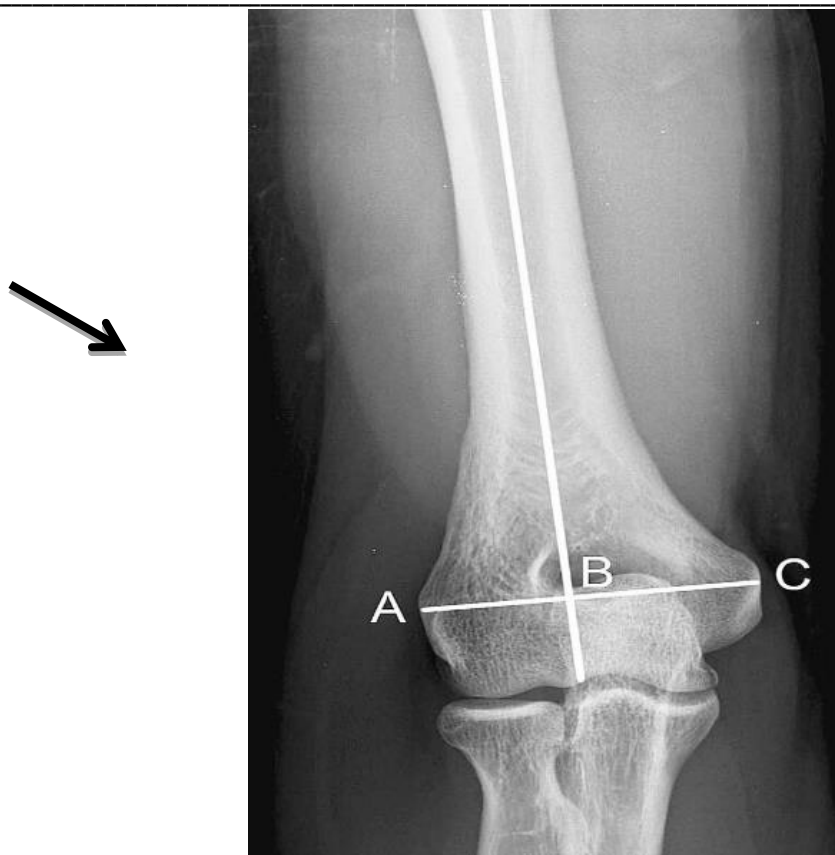
2. Step-cut osteotomy technique fixed with a single cortical screw: This needs careful pre-operative planning and special attention to surgical details. A step of bone is left on lateral metaphyseal aspect of the distal fragment after wedge removal followed by fixation with a single cortical screw. An unrecognized fracture of the cortical spike is a possibility which may lead to loss of fixation and persistent varus deformity<sup>(10)</sup> see figure (14). A modification of this method is the use of a Y-shaped humeral plate for firm fixation that allows early movement of the joint.<sup>(10)</sup>



**Figure(14)<sup>(10)</sup> Osteotomy designed to correct cubitus varus deformity of 13 degrees. Distal fragment can be rotated to correct additional deformity. After wedge removal and closure, screw is used for fixation .**

#### **Lateral condylar prominence index :**

Lateral condylar prominence is a recognized cosmetic complication following corrective osteotomy for cubitus varus . It is the bony prominence over the lateral condylar region of the humerus caused by lateral displacement of the elbow due to unequal widths of the proximal and distal fragments when closing the osteotomy .The lateral condylar prominence index (LCPI) is measured radiographically on anteroposterior view of elbow and calculated on the affected side as the difference between the measured maximum lateral and medial widths of the bone from the longitudinal mid humeral axis and was expressed as a percentage of the total width of the distal humerus to minimize errors from x-ray magnification . The lateral prominence condylar index (LCPI) =  $(AB - BC)/AC \times 100$  as shown in figure (15)<sup>(21)</sup>.The result is significant if the lateral condylar prominence index is more than 25% .



**Figure (15) Lateral condylar prominence index . (photographed by the researcher).**

AB= line of maximum lateral width to the longitudinal mid humeral axis .

BC= line of maximum medial width to the longitudinal mid humeral axis .

AC= line between the maximum lateral width to the maximum medial width of distal humerus .

Black arrow= longitudinal mid humeral axis .

### **Patients & Methods :**

This is a prospective study that was conducted from April 2010 to November 2011, at orthopedic unit of AL- Basrah general hospital . Seven children with established cubitus varus deformity complicating supracondylar fracture of humerus were included. In all of those patients ,a lateral closing wedge osteotomy in the supracondylar region of the humerus was performed . They were six boys and one girl. The average age at time of surgery was 7 years (range 3 to 10 years). The original injury was treated conservatively (closed reduction and splintage) in 5 patients and by open reduction and Krischner wires fixation in the remaining two patients .Involvement of right elbow was reported in 4 patients and left elbow in 3 .The cause of the original fracture was fall on an outstretched hand in all cases. The indication for osteotomy was cubitus varus deformity that was cosmetically unacceptable by the parents . Time interval between the original injury and the corrective surgery was 3-12 months .Preoperative assessment of the varus deformity was done both clinically and radiographically . A goniometer was used to make the clinical measurements of the carrying angle of both the involved and normal sides .

Radiographic assessments included true antero-posterior (AP) of both elbows taken with the forearm fully extended and supinated at elbow joints . On the tracing of the radiographs, the Baumann's angles on the deformed and normal limb were measured and recorded.

## Operative technique

The surgical procedure was performed with the patient in supine position and the involved limb held across the patient's chest by an assistant. At induction of anaesthesia, a third generation cephalosporin antibiotic was administered intravenously and continued at 12 hours interval for the next 24 hours. The dose was calculated according to body weight (150mg/kg/day in divided dosage). An Esmarch tourniquet was applied proximally in the arm. The posterior triceps splitting approach was utilized in all cases to expose the distal end of the humerus. The upper border of the olecranon fossa was visualized in every case. A laterally based wedge of bone was removed from distal humerus. The size of the wedge was the difference between Baumann's angle on the deformed and the healthy sides as calculated pre-operatively from the patient's antero-posterior radiographic tracings (each one degree=one millimeter of bone should be removed). The proposed wedge was first marked on distal humerus. Two cortical screws of proper length were then inserted into the lateral cortex and directed to engage the bone medially. One screw was positioned proximal and the another one distal to the osteotomy site, their heads were left untightened until the passage of circulage wires round them later on at the completion of the osteotomy. The osteotomy cut is performed using a reciprocal saw. The lower osteotomy is done first 1cm above the distal screw. The cut is performed transversely parallel to elbow joint. The proximal cut is performed 1cm below the proximal screw and is angled appropriately in an inferior and medial direction to meet the distal cut medially and thus to create the proposed wedge. The medial cortex of humerus and the periosteum are left intact during the cuts to create a medial cortical and periosteal hinge to allow better control of the lower fragment. After removal of bone wedge, the osteotomy gap is closed by breaking the medial hinge with gentle force, The desired correction is made and the cut surfaces are firmly apposed by tightening a tension band wire loop around the heads of the two screws in a figure of 8 fashion. The screws head are then gently tightened. The appearance of the elbow, the degree of correction and range of passive elbow motion are assessed. Wound closure was then performed after removal of the tourniquet, a long posterior arm slab is applied after completion of the operation with the elbow held in 90° flexion. The patient was discharged home next day and instruction on limb elevation and active movement of fingers were given. Follow-up visits were arranged at a weekly interval, the slab is removed after three weeks followed by a course of gentle passive and active movements of elbow (both flexion and extension). Healing of osteotomy site is followed radiographically till solid union is achieved. Removal of internal fixation is done 4 months postoperatively.

The lateral condylar prominence index (LCPI) is measured radiographically on anteroposterior view of elbow and calculated on the affected side post operatively. The results of treatment were graded as excellent, good or poor according Bellmore et al criteria.<sup>(24)</sup> Table(1)

**Table(1) Bellmore criteria for assessment<sup>(24)</sup>**

<b>Outcome</b>	<b>Difference in range of elbow motion</b>	<b>Difference in carrying angle</b>	<b>Lateral condylar prominence index</b>	<b>COMPLICATION</b>
<b>Excellent</b>	Difference < 10°	5-6	No increase	NONE
<b>Good</b>	Difference 10-20°	-10 6	Increase <25%	Minor
<b>Poor</b>	Difference >20°	>10	Increase > 25%	With residual defect or review surgery

**Early Lateral Closing Wedge Surgical Correction of Cubitus Varus Deformity Complicating Supracondylar Humeral Fracture in Children**

:Name  
:Age  
:Sex  
:Telephone number  
:**TRAUMA**  
:Time  
:Mechanism  
:**FRACTURE**  
:Type: closed: open  
Classification t1: t2: A / B t3: :  
:Associated Injury  
:Side: Lt: Rt  
:Treatment  
:Time interval between injury and the first presentation-  
: Time interval between injury and intervention-  
:?If delay intervention,why  
:Type of intervention-  
:Carrying angle at that time  
:Baumann's angle at that time

**(CUBITUS VARUS (pre operative**

: Baumann's angle -  
:carrying angle-  
range of motion-  
:time interval since injury-  
:type of surgery-  
:Approach  
:Calculation of wedge and amount of correction  
:Type of wedge  
:Postoperative management-  
  
:postoperative complications-  
:Postoperative angles-  
:Baumann's angle-  
:Carrying angle -  
: Range of motion -  
: Lateral condylar prominence index-  
:Deformity:-fully corrected-  
:partially corrected-  
:persisted-

**Results:**

The age of the seven patients included in the study ranged from 3-10 years (average 7 years) as shown in table 2 .

**Table -2- Age distribution and percentage**

Age (years)	No.	%
3	1	3.14
4	1	3.14
5	1	3.14
6	0	0
7	0	0
8	0	0
9	1	3.14
10	3	8.42
Total	7	100

Timing of corrective surgery ranged from 3-12 months (average 10 months) since the initial supracondylar fractures as shown in table 3

**Table -3- Time interval between supracondylar fracture and corrective osteotomy :**

Time(months)	No.	%
3-8	1	3.14
8-12	6	7.85
Total	7	100

The pre-operative Baumann's angle of the injured side ranges from 90° to 105° (average 95°) as shown table 4 .

**Table-4- Pre-operative Baumann's angle :**

Patient	Bauman n's angle		
	Injured side	Normal side	Difference
1	100°	78°	22°
2	105°	80°	25°
3	90°	77°	13°
4	95°	79°	14°
5	90°	75°	15°
6	100°	80°	20°
7	90°	76°	14°

The post-operative Baumann's angle of the deformed elbow ranges from 79°-84° (average 81°) as shown in table 5 .

**Table-5- Post-operative Baumann's angle :**

Patient	Baumann's angle		
	Corrected side	Normal side	Difference
1	80°	78°	2°

2	84°	80°	4°
3	80°	77°	3°
4	83°	79°	4°
5	79°	75°	4°
6	82°	80°	2°
7	80°	76°	4°

The pre-operative carrying angle of the injured side ranges from -10° to -22° with an average of(-15°) as shown in table 6 .

**Table-6- Pre-operative carrying angle :**

Patient	carrying angle		
	Injured side	Normal side	Difference
1	-20°	14°	34°
2	-22°	10°	32°
3	-12°	8°	20°
4	-10°	10°	20°
5	-11°	9°	20°
6	-20°	7°	27°
7	-10°	7°	17°

In one case the carrying angle of the affected elbow returned to that of the normal side . In the remaining 6 cases a difference in carrying angle between affected and normal sides ; the range of (1-3°) had remained post correction as shown in table 7 . The range of post corrective carrying angle is (6-13°) ,and the average is (9°)

**Table-7- Post-operative carrying angle :**

Patient	carrying angle		
	Corrected side	Normal side	Difference
1	13°	14°	1°
2	10°	10°	0°
3	7°	8°	1°
4	8°	10°	2°
5	7°	9°	2°
6	6°	7°	1°
7	6°	7°	1°

The amount of maximum elbow flexion before surgery was in the range from 133° to 140° (average 137°) as shown in table 8 .

**Table-8- Pre-operative range of elbow flexion :**

Patient	Elbow flexion in degrees		
	Injured side	Normal side	Difference
1	135	140	5
2	140	140	0



3	134	135	1
4	140	140	0
5	133	135	2
6	137	137	0
7	139	139	0

No flexion contracture was recorded in the study .The range of post –operative elbow flexion of the deformed limb; ranged from 132°-139° the average was (135°) as shown in table 9 .

**Table-9- Post-operative range of elbow flexion :**

Patient	Elbow flexion in degrees		
	Corrected side	Normal side	Difference
1	139	140	1
2	136	140	4
3	134	135	1
4	138	140	2
5	132	135	3
6	134	137	3
7	135	139	4

All children were followed up after the removal of the implant when achieving fracture union . The minimum follow –up period was 6 months ; (range 6-9 months) .

Neither wound infection nor implant failure were reported in the study. Tourniquet nerve palsy was also not recorded . There is no any post operative significant difference of lateral condylar prominence index (LCPI) from pre- operative one of the deformed limbs detected in this study in a period ranges from 6-9 months of follow up ,as shown in table 10 .

**Table-10- Pre and post operative Lateral condylar prominence index :**

Patient	Lateral condylar prominence index		
	Pre-operative %	Post –operative %	Difference %
1	5.8	5.9	No increase
2	7.1	7.3	No increase
3	6	6	No increase
4	5.2	5.3	No increase
5	7.5	7.6	No increase
6	6.7	7	No increase
7	5.9	6.0	No increase

All seven patients had gained excellent results with in a minimum of 6 months follow up , table (11) .

**Table -11- Results according to a protocol from Bellmore et al<sup>(24)</sup> :**

Results	No.	%
excellent	7	100%
good	0	0

---

poor	0	0
------	---	---

---

### Discussion:

One of the most common late complication of supracondylar fracture of the humerus in children is cubitus varus . The deformity represents fracture malunion resulting from inadequate reduction or loss of reduction of fracture .It is not progressive and doesn't improve by remodeling with time<sup>(25,26,27)</sup> . The treatment of cubitus varus is surgical correction . Cubitus varus is disfiguring .The indication of surgical correction is not only the cosmetic concern ,but also to avoid other complications as secondary humeral fractures and latent posterolateral instability of the elbow <sup>(28,29,30)</sup> when the deformity is allowed to persist for along period of time without correction . A secondary fracture of distal humerus after union of supracondylar fracture in cubitus varus is increasingly reported in the literatures .Such secondary fractures to distal humerus might be an epiphyseal injuries as reported by Takahara et al .<sup>(31)</sup> or lateral condylar fracture as reported by David et al <sup>(19)</sup> ,and Mohd Iqbal et al <sup>(32)</sup> . Biomechanical analysis by these authors suggested that posttraumatic cubitus varus alignment could increase both the distraction and shear forces across the lateral condyle of the distal humerus generated by a routine fall on an outstretched hand<sup>(32)</sup> . In all seven cases in this study ,the indication for surgery was the unacceptable appearance of the injured limb . The parents were so anxious about the limb deformity of their children .

The timing of corrective osteotomy for cubitus varus remains controversial. Several authors recommended delaying the operation until late in puberty to reduce the rate of deformity recurrence<sup>(33,34)</sup> . But since the deformity is the result of malunion rather than growth disturbance and is not progressive ,many authors agree that the deformity can be corrected permanently by an early corrective osteotomy rather than waiting after skeletal maturity <sup>(5,20,21,26)</sup> . This study agree with the idea of early correction of posttraumatic cubitus varus following supracondylar fracture. We think that the advice to wait for future correction of the established cubitus varus till near skeletal maturity is practically not effective in our locality .The family concern about deformity is tremendous and most patients and their parents are usually lost during the follow up and many of these patients may not receive any corrective treatment in the future .Leaving these deformities uncorrected to adult life is associated with the possibility of late posterolateral rotatory instability of the elbow several years after cubitus varus secondary to pediatric supracondylar fracture as shown by many authors <sup>(28,30)</sup> .

Jain et al <sup>(11)</sup> believed that the best age to correct cubitus varus deformity is 6-11 years . By 6 years of age, there is enough bone at the lower end of the humerus to permit adequate stable fixation of the distal fragment, avoiding possible damage to the distal humeral epiphysis, following a lateral closed wedge osteotomy. Three of children in this study were below 6 years of age at time of corrective surgery and we didn't face the problem of inadequate bone quantity at distal humerus since the healing callus during early months following the fracture is abundant in amount ,this will add to the size of the original bone at the proposed site of osteotomy making wedge removal feasible even when the patient's age at surgery is below 6 years . By using French method for fixing the osteotomy site we found that the fixation device is not bulky and there is always a room for insertion of one screw in the distal fragment even in a very small child .We also think that performing corrective surgery early in the young child the healing process is more powerful and takes shorter time than in the old child approaching skeletal maturity . The potential to regain full range of elbow motion is higher when compared to with the operation performed on the old child or adult .

The development of unsightly lateral prominence of the elbow joint following corrective osteotomy of posttraumatic cubitus varus had been recorded by many authors <sup>(5,11,20,21)</sup> . This lateral condylar prominence is attributed to the unequal width of the two fragments at the osteotomy site . Lateral condylar prominence will usually remodel with time if corrective surgery is performed in early life particularly in less than 11 years of age <sup>(11)</sup> , which allows a period of 2-3 years of remodeling before skeletal maturity . In other words if correction of cubitus varus is delayed until near skeletal maturity , the ugly lateral condylar prominence of

elbow will remain uncorrected . This means that the main purpose of cubitus varus corrective surgery (i.e improving the cosmetic appearance) is not fulfilled . We think that early correction will benefit the patient allowing more chance of remodeling at the osteotomy site .Lateral condylar prominence was not reported in this study ,this probably due to the fact that all children in the study had their cubitus varus below 23°. Several authors <sup>(11,21)</sup> had reported lateral prominence when the varus deformity is 30° or more . In such cases larger size of wedge had to be removed from distal humerus increasing the possibility of mismatch in the width of the proximal and distal fragments .We believe that the shortcoming of this study is the small number of cases studied and the short period of follow-up of 6-9 months . Longer follow-up period is needed to determine the true results of this operation . But the results of our study are comparable to previous studies that have dealt mainly with short-term results <sup>(6, 26,35,36)</sup> .

### **Conclusion :**

Early lateral closing wedge osteotomy to correct posttraumatic cubitus varus as soon as the elbow can be fully extended by the child is reasonable for poor compliance patients .

### **Recommendations :**

- 1- We recommend early correction (with in one year) of posttraumatic cubitus varus following supracondylar fracture because The family concern about deformity is tremendous and most patients are usually lost during the follow up period .
- 2- Further study with large number of cases and a longer period of follow-up is needed to determine the true long term results of this operation .

### **References:**

- 1.Srivastava AK, Srivastava DC, Gaur SC. Lateral closed wedge osteotomy for cubitus varus deformity. Indian J Orthop 2008;42:466-70
- 2.Jimulia TR, Sabnis SK. Supracondylar corrective osteotomy for cubitus varus--the internal rotation component and its importance. An unique bone experiment. J Postgrad Med 1994;40:194
3. Carlson CS, Rosman MA. Cubitus varus: a new and simple technique for correction. J Pediatr Orthop 1982;2:199–201.
- 4.Kumar, Kapil ,Sharma, Vinod K, Sharma, Rajbahadur , and; Maffulli, Nicola . Correction of Cubitus Varus by French or Dome Osteotomy: A comparative Study. Journal of Trauma-Injury Infection & Critical Care October 2000 - Volume 49 - Issue 4 - pp 717-721
5. Barrett IR, Bellemore MC, Kwon YM. Cosmetic results of supracondylar osteotomy for correction of cubitus varus. *J Pediatr Orthop*1998;18:445-7.
6. McCoy GF, Piggot J. Supracondylar osteotomy for cubitus varus: the value of the straight arm position. *J Bone Joint Surg [Br]* 1988;70-B: 283-6.
- 7.Sangwan SS, Marya KM, Siwach RC, Singh Z, Devgan A. Cubitus varus - correction by distraction osteogenesis. Indian J Med Sci 2002;56:165-71
- 8."Cubitus Varus - Wheelless' Textbook of Orthopaedics". [http://www.wheelsonline.com/ortho/cubitus\\_varus](http://www.wheelsonline.com/ortho/cubitus_varus) Retrieved 2008-02-25..
9. Louis salomon Apley's system of orthopedic and fractures .chapter 24, Injuries of shoulder, upper arm and elbow ,9<sup>th</sup> Edition, (2010) P-758

10. S Terry Canale, Chapter 33,Fracture and Dislocations in children, Campbell's Operative Orthopedic, 11<sup>th</sup>, Edition, (2008) ,P 1583.
11. A. K. Jain · I. K. Dhammi · A. Arora · M. P. Singh · J. S. Luthra.Cubitus varus: problem and solution.Arch Orthop Trauma Surg (2000) 120 :420–425
- 12.Laupattarakasem W, Mahaisavariya B. Stable fixation of pentalateral osteotomy for cubitus varus in adults. J Bone Joint Surg Br 1992;74:781–2.
13. Snell RS. Clinical anatomy by regions 8<sup>th</sup> Edition Lippincott Williams and Wilkins. (2008), chapter 9, P 511
- 14.LUTZ VON LAER, M.D, Pediatric Fractures and Dislocations. Chapter 19 ,4<sup>th</sup> Edition (2004),p 134 .
15. Dodge HS. Displaced supracondylar fractures of the humerus in children : treatment by Dunlop's traction. J Bone Joint Surg[Am] 1972;54-A :1408-18.
16. Reinaerts HH, Cheriex EC. Assessment of dislocation in the supracondylar fracture of the humerus, treated by overhead traction. *Reconsir Surg Traumatol* 1979 : I 7:92-9.
17. Oppenheim WL, Calder TJ, Smith C, et al: Supracondylar humeral osteotomy for traumatic childhood cubitus varus deformity. *Clin Orthop Relat Res* 1984; 188:34.
- 18.John A. Herring, MD, Tachdjian's pediatric orthopaedics,4<sup>th</sup> edition (2008),volume3,section4,chapter42,3mht
- 19.David J. R., Maguire M.F., Mubarak S. J., Wegner D.R. Lateral condylar fracture of the humerus following post-traumatic cubitus varus .*J.Pediatr.Orthop.*,1994,14,466-470
20. Pankaj A, Dua A, Malhotra R, Bhan S. Dome osteotomy for posttraumatic cubitus varus: a surgical technique to avoid lateral condylar prominence. *J Pediatr Orthop* 2006;26:61-66.
21. Wong HK, Lee EH, Balasubramaniam P. The lateral condylar prominence: a complication of supracondylar osteotomy for cubitus varus. *J Bone Joint Surg Br* 1990;72:859-61.
22. Tachdjian MR. Osteotomy of distal humerus for correction of cubitus varus. In: Smith AB, editor. *Pediatric Orthopedics*. Philadelphia: WB Saunders; 1972. p. 1588-91.
23. Oppenheim WL, Clader TJ, Smith C, Bayer M. Supracondylar humeral osteotomy for traumatic childhood cubitus varus deformity. *Clin Orthop* 1984; 188:34-39..
24. Bellemore MC, Barrett IR, Middleton RWD, Scougall JS, Whiteway DW. Supracondylar osteotomy of the humerus for correction of cubitus varus. *J Bone Joint Surg [Br]* 1984;66-B:566-72.
25. DeRosa GP, Graziano GP. A new osteotomy for cubitus varus. *Clin Orthop Relat Res* 1988;236:160-5.
26. KING, DON, and SECOR, CHARLES: Bow Elbow (Cubitus Varus). *J. Bone and Joint Surg.* , 33-A: 572-576, July 1951
27. Kumar K, Sharma VK, Sharma R, Maffulli N. Correction of cubitus varus by French or dome osteotomy: a comparative study. *J Trauma*2000;49:717-21.
28. Abe M, Ishizu T, Morikawa J. Posterolateral rotatory instability of the elbow after posttraumatic cubitus varus. *J Shoulder Elbow Surg* 1997; 6:405-9.

29. O'Driscoll SW, Spinner RJ, McKee MD, et al. Tardy posterolateral rotatory instability of the elbow due to cubitus varus. *J Bone Joint Surg. Am* 2001;78:1358-69.
30. Osada D, Kameda M, Tamai K. Persistent posterolateral rotatory subluxation of the elbow in cubitus varus: a case report. *Hand Surg.* 2007;12:101-5.
31. Takahara M, Sasaki I, Kimura T, et al. Second fracture of the distal humerus after varus malunion of the supracondylar fracture in children. *J Bone Joint Surg Br* 1998;80:791-7.
32. Mohd Iqbal, Asif Sultan, Mubashir Maqbool et al. Lateral condylar fractures of humerus in children following varus malunion of supracondylar fracture. *The internet Journal of orthopedic Surgery*. ISPUB.com. Internal Scientific publication. ISSN: 581-2963.
33. Ippolito E, Moneta MR, D'Arrigo C. Post-traumatic cubitus varus. Long-term follow-up of corrective supracondylar humeral osteotomy in children. *J Bone Joint Surg Am* 1990;72:757-65.
34. Smith L. Deformity following supracondylar fractures of the humerus. *J Bone Joint Surg Am* 1960;42:235-52.
35. ALONSO-LLAMES, M. ; PELETIER, R. D. ; and MARTIN, A. M. : The Correction of Post-Traumatic Cubitus Varus by Hemi-Wedge Osteotomy. *Internat. Orthop.* , 2: 215-218, 1978.
36. DEROSA, G. P. , and GRAZIANO, G. P.: A New Osteotomy for Cubitus Varus. *Clin. Orthop.* , 236: 160-165, 1988.