

Selection Of Treatment Methods For Patients With Multiple Fractures Of Lower Extremity Bones

Shukurov E.M. Soipov R.R.

Tashkent Regional Branch of RRCEM, Uzbekistan

Republican Scientific and Practical Center of Traumatology and Orthopedics. Tashkent. Uzbekistan.

The aim of the study is to improve the results of treatment of patients with multiple lower extremity fractures by optimizing complex diagnostics and minimally invasive methods of external and internal fixation.

The experience of treating 220 patients with multiple fractures of the long bones of the lower extremities in the clinic of the Republican Scientific and Practical Center of Traumatology and Orthopedics from 2016 to 2022 is presented.

The authors developed wire-rod devices based on parts of the Ilizarov apparatus and put them into practice among traumatologists. The developed devices are used in combination with modern minimally invasive methods such as BIOS and MIPO. The results of treatment were studied comparatively.

Results: Surgical treatment (177 - 80.5%) consists of using various methods of external fixation devices based on wires and rods in patients. Modern methods of treatment of long bone fractures include intramedullary rods and interosseous locking platinum AO for the femur and tibia. Early complications were observed in 30 (20.4%) of 147 patients who underwent surgery. In 39 of 147 patients, late complications were observed in various methods of treatment of multiple fractures of the lower extremities. The most reasonable methods in the treatment of multiple fractures of the lower extremities are locking and combined use of hardware-surgical methods and intramedullary osteosynthesis. external fixation devices that have been proven to increase the effectiveness of positive results up to 83.3%.

Key words: multiple fractures, early and late complications, external fixation devices, modern treatment technologies.

The aim of the study is to improve the results of treatment of patients with multiple fractures of the bones of the lower extremities by a combination of external and internal fixation. The aim of the study is to improve the results of treatment of patients with multiple fractures of the bones of the lower extremities by a combination of external and internal fixation.

Materials and methods: The experience of treating 220 patients with multiple fractures of the long bones of the lower extremities, who underwent inpatient treatment at the Republican Specialized Scientific and Practical Center of Traumatology and Orthopedics for the period from 2016 to 2022, is presented.

Introduction. Multiple fractures of the bones of the musculoskeletal system, along with associated and combined injuries, belong to a large group of polytraumas. [1,4]

Among the early complications of severe multiple and combined fractures of the bones of the extremities, first of all, we should note the complications related to the violation of the rheological properties of blood: fat embolism syndrome, thrombosis of the veins of the lower extremities, thromboembolism. pulmonary artery, cerebral vessels. [5,11,14]. Multiple fractures are often associated with traumatic shock, deep vein thrombosis (DVT), pulmonary embolism (PE), and fat embolism (FE). [8,9]. Among the main causes of death in the early stages of the development of a traumatic disease, many authors note fat embolism syndrome, thrombosis of lower extremity vessels [15, 5] and pulmonary embolism [13, 16]. The most common complications of fractures of lower extremity bones are pseudarthrosis and nonunion of long bones (23.2%), development of osteomyelitis (0.4-22.4%), [6]. In open fractures, these complications account for approximately 27.0% [4,11,12].

In recent years, the proportion of patients with multiple fractures of the bones of the lower extremities and associated injuries “has reached 25–28% of the total number of trauma patients, ranging from 6.6% to 75.5%.” [4].

According to WHO, “..in the structure of overall mortality, mortality from polytrauma ranks third..” after mortality from cancer and cardiovascular diseases, and in the group of men aged 18 to 40 years, polytrauma is the main cause of death. [2, 3]

For the effective treatment of multiple fractures of the long bones of the lower extremities, improvement of osteosynthesis methods, prevention of complications, introduction of modern technologies, as well as timely provision of medical care to patients with improvement of their quality of life remains relevant [12, 7]. The Ilizarov method is traditionally used in the treatment of severe open fractures accompanied by tissue defects or purulent complications [2, 3, 4, 15].

Various methods of external fixation of bone fragments are being developed, including various original and improved modifications of the Ilizarov apparatus, pin-rod devices and external fixation locking plates [2, 3, 10, 14].

Research is being conducted on stabilizing functional transosseous osteosynthesis, also intramedullary locking osteosynthesis (BIOS), minimally invasive plate osteosynthesis (MIPO), local compression plates (LCP), reconstructive plates, stabilizing at an angle and others [6,4,11,12].

It should be noted that despite the significant achievements of medical science, solving many problems of minimally invasive osteosynthesis technology in the period of early rehabilitation remain pressing problems.

The purpose of the study is to improve the results of treatment of patients with multiple lower extremity fractures by optimizing complex diagnostics and minimally invasive methods of external and internal fixation.

MATERIAL AND METHODS

The work is based on the experience of treating 220 patients with multiple fractures of the long bones of the lower extremities who underwent inpatient treatment at the clinic of the Republican Specialized Scientific and Practical Center for Traumatology and Orthopedics for the period from 2016 to 2022. Of these, 180 (82%) patients were male, 40 (18.2%) patients were female.

The average age of the patients was 40.5 ± 11.9 years. Of the total number of victims, 187 had traumatic shock, 160 (85.6%) had grades I-II. 20 (10.7%) people were in a state of severe shock or terminal condition. The most frequently observed fractures were the femur and tibia in 108 (24.5%) patients, the tibia in 166 (37.7%) and the femur in 30 (6.8%). The overwhelming majority (153 - 69.5%) of patients had closed fractures, open fractures were observed in 67 (30.5%) victims

The severity of open fractures was assessed according to the classification of A.V. Kaplan, O.N. Markova (1975). According to this classification, the most common injuries in patients were type I (26 - 38.8%) and type II (23 - 34.3%). Type III injuries (18 – 26.9%) were recorded somewhat less frequently.

In 170 patients, fractures were combined with damage to other segments in the following order: traumatic brain injury - 78 (45.9%), humerus fractures - 16 (9.4%), 10 (5.9%), spinal fracture 18 (10.6%), clavicle fractures - 6 (3.5%), pelvic bone fracture - 12 (7%), calcaneal fracture - 14 (8.2%), patellar fracture - 8 (4.7%), fractures ribs - 8 (4.7%).

Mixed fat embolism was observed in 28 (12.7%) patients, mainly (71.4%) on days 2-3 after admission. In 33 (15.0%) patients, mainly with fractures of the tibia and combined fractures of the tibia and femur, deep vein thrombosis of the lower extremities developed more often on days 2-6.

Timely diagnosis of thrombosis of the veins of the lower extremities is one of the determining tactics for treating patients with multiple fractures of the bones of the lower extremities.

Currently, the main instrumental method for diagnosing DVT is ultrasound angio scanning of the veins of the lower extremities. Ultrasound Doppler scanning of the vessels of the lower extremities was performed before and after surgery to identify deep vein thrombosis of the lower extremities, assess the condition of the walls, the lumen of the veins, determine the localization of thrombosis, its extent, duration of occurrence and degree of fixation to the vascular wall.

An analysis of the characteristics of medical care showed that more than half (55.9%) of the patients were operated on on days 2-6, and almost a third (30.9%) on days 7-10 after hospitalization.

Analysis of the characteristics of medical care showed that more than half (55.9%) of the patients were operated on on days 2-6, almost a third (30.9%) on days 7-10 after hospitalization (Table 1)

Table No. 1.

Distribution of patients with multiple fractures of the long bones of the lower extremities depending on the timing of surgery

Fracture location	Day			Total	
	2-6-e	7-10-e	>10	abs.	%
Femur-tibia	40	23	14	77	35,0
Shin	69	35	8	112	50,9
Hip	14	10	7	31	14,1
Total, abs. (%)	123 (55,9)	68 (30,9)	29 (13,2)	220	100,0

The average period of osteosynthesis after injury was 27 days. The average length of inpatient treatment is 14 days.

After a standard clinical and laboratory examination, in the absence of contraindications, osteosynthesis was performed using various treatment methods. In 43 (19.5%) of 220 patients, conservative treatment of fractures (plaster cast) became the method of choice. The reasons for conservative treatment were pathologies of the lungs, cardiovascular system and somatic diseases associated with the patient's age (over 70 years old with open fractures), and the patient's disagreement with surgical intervention.

Surgical treatment (in 177 - 80.5%) patients consisted of the use of various methods of external fixation devices based on wires and rods.

Among the modern methods of treating long bone fractures, locking intramedullary rods for the femur and tibia and AO interosseous locking platins were used.

Of the 147 victims, the Ilizarov apparatus was installed in 54 (36.7%) patients, external fixation devices in our modification (AVFm) - 48 (32.7%), BIOS - 12 (8.2%), BIOS + AVFm - 15 (10.2%), external osteosynthesis - 18 (12.2%).

Based on Ilizarov's designs, a number of apparatus arrangements for osteosynthesis of long bones of the lower extremities have been developed. In the spoke-rod version, 4 half-rings of the Ilizarov apparatus are used as an external support, on which a screw tie is fastened. Transosseous fixators are wires and rods of different diameters from 4 mm to 6 mm, and each bone rod has a screw part and a cylindrical part with a turnkey shank. (FAP 00307, 08/14/2007), (FAP00755, 05/05/2011). The third modification is a rod apparatus for osteosynthesis of fractures of long bones of the lower extremities with two half rings and two strips from the Ilizarov apparatus, on which there are threaded rods (FAP 00738, 06/23/2012). A rod apparatus for the treatment of fractures of long bones contains a rod, threaded throughout, on which four lanyards with threaded holes, bone rods, rod holders with holes for the rod and bone rods, and nuts for rigid fixation of the lanyards are installed. (FAP2023.0097.dated 03.17.23.).

The choice of treatment methods depended on the location, number and nature of fractures, as well as the timing of the injury.

RESULTS AND DISCUSSION. The difficulty of treating patients with multiple fractures of the lower extremities is due to the severity of damage not only to bones and concomitant injuries, but also to early complications, such as deep vein thrombosis and pulmonary embolism, fat embolism. [5, 8, 9]. To improve the diagnosis and treatment of patients with multiple fractures of the lower extremities, we have developed an algorithm for the diagnosis and treatment of patients with multiple injuries of the lower extremities. (No. DGU 02308 dated 09/06/2011).

The initial examination of the patient and the provision of intensive anti-shock infusion therapy and diagnostic measures to patients with fractures of the bones of the lower extremities was carried out in the emergency department according to the algorithm and the proposed tactics of diagnosis and treatment, prediction of complications of multiple fractures of the bones of the lower extremities (No. DGU 02318 dated 12.09.2011). Patients with combined trauma, with damage to internal organs, in need of emergency care, after recovery from a state of shock with immobilization of the limbs, after examination by a specialist for further continuation of anti-shock therapy and dynamic observation, the patients were hospitalized in the intensive care unit.

In order to prevent pulmonary embolism and thromboembolic complications, rheologically active drugs are used in combination with antiplatelet agents and anticoagulants. For early prevention of fat embolism, lipotropic drugs that prevent lipid disemulsification are recommended. When primary symptoms of fat embolism appeared (impaired consciousness, mental inadequacy, agitation, the appearance of a petechial rash on the skin of the chest, delirium), mechanical ventilation was performed.

In case of severe combined injury, occurring with complications such as traumatic shock, fat embolism, venous thrombosis (PE), two-stage osteosynthesis was performed. Tactics and methods of treating bone fractures are carried out in an emergency, delayed and planned manner, depending on the general condition of the patient, the location and nature of the fractures, and the presence of concomitant injuries to internal organs. [1, 4, 10, 3] Taking into account the general condition of the victim, stabilization of fractures is carried out using plaster casts; for open fractures, less traumatic methods of external fixation, intramedullary locking rods. After stabilizing the general condition of the victim, modern treatment technologies are used, such as locking intramedullary rods and locking plates (LCP) of the AO type.

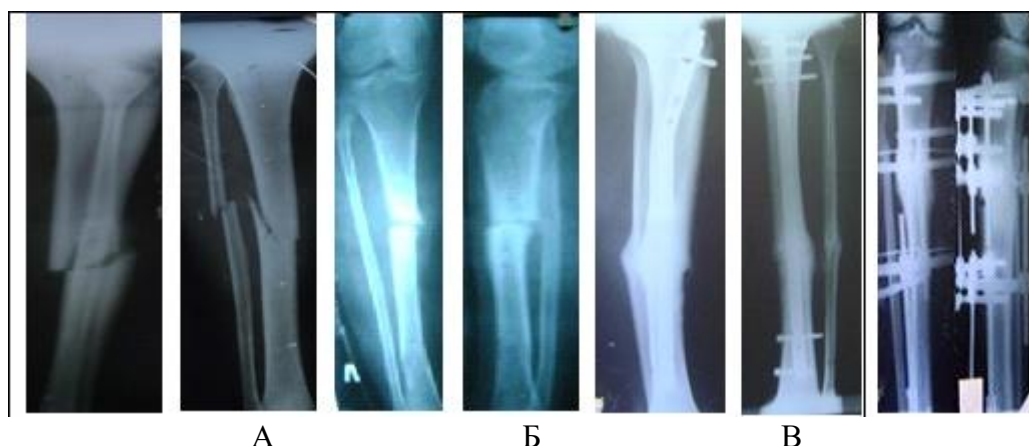According to our observations, out of 220 patients with multiple fractures of the lower extremities, fat embolism developed in 28 (12.7%), mainly in persons with bilateral fractures. 9 (32.1%) victims had open fractures.

All 28 patients had a subacute form of fat embolism, which developed after the so-called "light interval", the duration of which in 3 (10.7%) patients was one day, in 17 (60.7%) – two days, in 8 (28.63%) – more than three days. On average, PVCs developed on 3.4 ± 2.2 days. All patients had impaired consciousness from stupor (23 - 82.1%) to coma (5 - 17.9%).

After stabilization of the condition (no earlier than 72 hours), osteosynthesis of fractures of the limb segments was performed. On average, stabilization of the patients' condition occurred after 7.3 ± 2.5 days of hospital treatment. Death occurred in 2 (7.1%) victims.

Intramedullary blocking osteosynthesis without drilling the bone canal was the best prevention of fat embolism.

Clinical example: Patient M., 22 years old. The injury was sustained as a result of an accident. After clinical and radiological studies, the diagnosis was made: Multiple trauma, open fracture of the middle third of the bones of the right leg with displacement of bone fragments, closed fracture of the middle third of the bones of the left leg with displacement of bone fragments



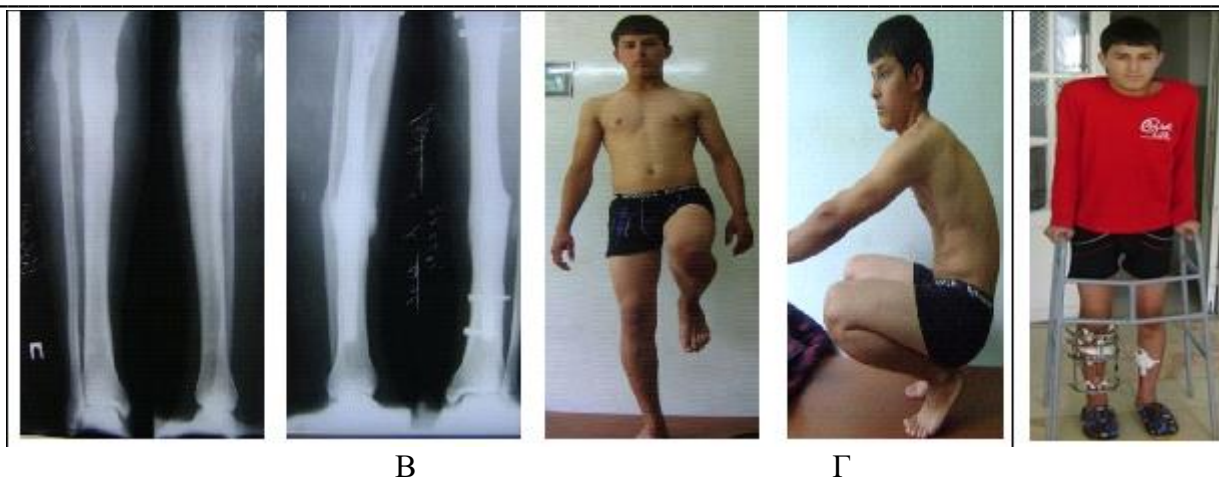


Fig. 1. Osteosynthesis with a locking pin and pin-rod device: radiograph of the patient upon admission (a), radiograph and view of the patient after surgery (b), radiograph after 6 months (c), view of the patient after 12 months (d)

The patient underwent a clinical and radiological examination, the patient was hospitalized in the shock ward and intensive anti-shock infusion therapy was started. In the intensive care unit, on the 3-4th day, against the background of intensive measures, the patient developed a picture of PVCs (tachycardia >120 beats/min, fever more than 38°C, drowsiness, impaired consciousness - stupor, on the anterolateral surface of the chest, on the skin a petechial rash appeared on the neck and mucous membranes). An X-ray examination of the lungs revealed scattered small foci of darkening in the form of a “snow storm.” Urine was examined for the presence of fat (+++).

The patient underwent treatment tactics according to the algorithm we developed: prevention of fatty and thromboembolism was carried out, procedures were prescribed for the physiological dissolution of neutral fat in the blood using fat disemulsifiers, and detoxification therapy.

Against the background of intensive therapy for fat embolism, after stabilization of the patient’s parameters and general condition, two teams of traumatologists performed BIOS of the left tibia. Considering that the patient had an open fracture of the middle third of the bones of the right leg with displacement of bone fragments, osteosynthesis of the bones of the right leg was performed using a pin-and-rod apparatus of our design. The postoperative period proceeded smoothly, the wounds healed by primary intention. After 3 months, the wire-rod apparatus was removed from the right shin. A year later the patient returned to his previous job.

Results. This part of the study was divided into two stages. At the first stage, early and late complications that arose during the treatment of patients with multiple fractures of the long bones of the lower extremities were studied. At the second stage, an analysis of the immediate and long-term results of treatment of patients using various methods of surgical treatment was carried out.

Of the 147 patients who underwent surgical treatment, 30 (20.4%) experienced early complications in the following order: inflammation of the soft tissues around the pins and rods, necrosis of the skin around the wounds, migration of the fixator, excessive length of the locking screws, fracture of the fixator, migration of the distal screws, fracture of the rod against the background of a healing fracture and pressure sores (Table 2). When signs of inflammation appeared (pain in the area of the wire, swelling, hyperemia, increased temperature, both local and general), antibiotics were prescribed to chip the soft tissue around the wires.

Table No. 2

Early complications in various methods of treating multiple fractures of the lower extremities

Complication	AI, n=54		AVFm, n=48		BIOS, n=12		BIOS+ AVFm, n=15		NO, n=18		Total, n=147	
	abs	%	abs	%	abs	%	Abs	%	abs	%	abs	%

Inflammation of soft tissues around wires and rods	10	18,55	10,4	1	8,3	-	-	2	1,1	18	12,2	
Necrosis of the skin around wounds	-	-	-	1	8,3	1	6,7	1	5,6	3	2,0	
Fixative migration	1	1,9	1	2,1	-	-	-	1	5,6	3	2,0	
Excessive length of locking screws	-	-	-	-	-	1	6,7	-	-	1	0,7	
Fixator fracture	-	-	1	1	8,3	-	-	1	5,6	2	1,4	
Migration of distal screws	-	-	-	-	-	1	6,7	-	-	-	0,7	
Fracture of the rod against the background of a healing fracture	11	8,5	7	10,4	1	8,3	-	-	2	11,1	18	12,2
Bedsore	-	-	-	-	1	8,3	1	6,7	1	5,6	3	2,0
Total	1	1,9	1	2,1	-	-	-	-	1	5,6	3	2,0

Secondary displacement of bone fragments after osteosynthesis with external fixation devices was observed in 6 patients, of which 5 patients with fractures of the tibia and one with a fracture of the femur. The reasons for the secondary displacement of bone fragments were non-compliance with the rules of transosseous osteosynthesis when performing the operation, applying an external fixation device and passing the wires through the bone, as well as their insufficient number to create rigid fixation in the external fixation device. Loosening of the fixation of the end of the main reduction pins, rods or their fractures were the main reasons for repeated displacement of the fragments.

Contractures of the knee and ankle joints due to fractures of the femur and shin bones were observed in 4 patients.

The average range of motion in the knee joint one month after surgery in patients with diaphyseal fractures was 98.9±4.6 degrees. Within one year, these indicators increased respectively to 133.4±2.5, 134.1±4.4 and 126.7±7.5 degrees.

With blocking intramedullary osteosynthesis after a year, the average amplitude was 132.5±2.8 degrees. According to the set objectives, we studied the immediate and long-term results of surgical treatment of patients with multiple fractures of the bones of the lower extremities.

Table No. 3

Late complications with various methods of treating multiple fractures of the lower extremities

Complication	AI, n=54		AVFm, n=48		BIOS, n=12		BIOS+ AVFm, n=15		NO, n=18		Total, n=147	
	abs	%	asb.	%	abs.	%	abs.	%	abs.	%	abs	%
False joint	2	3,7	1	2,1	1	8,3	-	-	1	5,6	5	3,4
Displacement of fragments	3	5,6	1	2,1	-	-	-	-	2	11,1	6	4,1
Wound suppuration	2	3,7	1	2,1	-	-	-	-	-	-	3	2,0
Slow consolidation	2	3,7	1	2,1	1	8,3	1	6,7	1	5,6	6	4,1
Joint contracture	2	3,7	-	-	-	-	-	-	2	11,1	4	2,7
Self-dynamization nail	-	-	-	-	6	50,0	6	40,0	-	-	12	8,2
Shin deformity	1	1,9	1	2,1	-	-	-	-	-	-	2	1,4
Soft tissue atrophy	-	-	-	-	-	-	-	-	1	5,6	1	0,7

Total	12	8.1	5	3.4	8	5.4	7	4.8	7	4.8	39	26.5
-------	----	-----	---	-----	---	-----	---	-----	---	-----	----	------

We have received a patent (No. DGU 03874 dated July 19, 2016) for a program for electronic computers “Program for examining patients with multiple fractures of the lower extremities.”

The developed examination card made it possible to determine the outcome of patient treatment according to objective and subjective criteria. The outcome of treatment of patients with multiple fractures, assessment of the results of treatment of fractures of long bones of the lower extremities were assessed according to the criteria proposed by E.R. Mattis [7].

81 (55.1%) results were considered good: absence of complaints after treatment, restoration of the anatomical form and function of the injured limb, and return of the victim to previous activities (Table 4). 57 (38.8%) considered the results satisfactory when patients still had complaints of intermittent pain in the injured limb, periodic fatigue, and forced use of additional support (crutches, canes) during long walking.

Table No. 4

Immediate results of treatment (up to 1 year) of patients with multiple fractures of the lower extremities according to E. Mattis (1984), n=147

Results	AI, n=54		AVFm, n=48		BIOS, n=12		BIOS+AVFm, n=15		NO, n=18		Total, n=147	
	abs	%	abs	%	abs	%	abs	%	abs	%	abs	%
Good	28	51,9	31	64,6	5	41,7	10	66,7	7	38,9	81	55,1
Satisfactory	23	42,6	16	33,3	5	41,7	4	26,6	9	50,0	57	38,8
Unsatisfactory		5,6	1	2,1	2	16,6	1	6,7	2	11,1	9	6,1
Total	54	36,8	48	32,6	12	8,1	15	10,2	18	12,3	147	100

We studied long-term treatment results from 1 year to 5 years in 120 patients, which is 54.5% of the total number of patients treated. In 2 patients with hip fractures, shortening of 2-3 cm was noted.

Anticurvatura deformity of up to 10 degrees was also found in 2 patients. Contracture in the knee joint was observed in 1 patient.

In 3 victims with fractures of the femur and tibia, false joints, deformation and shortening of the limbs were registered.

Five patients experienced pain in the operated limb during prolonged walking and heavy physical work.

In general, the majority of patients achieved a good treatment outcome compared with the outcome indicator before 1 year (82.5% vs. 55.1%; OR 3.84; 95%CI 2.17-6.81; p<0 .0001) (Table No. 5).

Table No. 5.

Long-term (from 1 year to 5 years) results of treatment of patients with multiple fractures of the lower extremities according to E. Mattis (1984), n=120

Result	AI, n=46		AVFm, n=42		BIOS, n=9		BIOS+AVFm, n=12		NO, n=11		Total, n=120	
	abs	%	abs	%	abs	%	abs	%	abs	%	abs	%
Good	36	78,3	38	90,5	7	77,8	10	83,3	8	72,7	99	82,5
Satisfactory	8	17,4	4	9,5	1	11,1	2	16,7	1	9,1	6	5,0

Unsatisfactory	2	4,3	-	-	1	11,1	-	-	2	8,2	5	4,2
----------------	---	-----	---	---	---	------	---	---	---	-----	---	-----

Thus, a comparative analysis of the results of surgical treatment of patients with multiple fractures of the lower extremities showed that in the long term, better results were achieved in patients treated with external fixation devices (90.5%) and their combination. with minimally invasive modern methods (83.3%).

References:

1. Agadzhanyan V.V. Polytram – Novosibirsk Science. 2003.-492 p.
2. Sysenko Yu.M. The role of transosseous osteosynthesis in the complex treatment of patients with multiple bone fractures. Journal.Polytrauma 2011.No.4. P.23.28.
3. Artemiev A.A. Brizhan L.K., Davydov D.V., Ivashkin A.N., Grigoryev M.A., Hassan Mohammed H.Yu., Kashub A.M., Gyanjaliyev R.A. Osteosynthesis according to Ilizarov as a self-sufficient method of treatment of shin bone fractures.//Journal. Polytrauma 2021. No. 1. Q. 51.59.
4. Ayvazyan V.P. Malkhasyan I.E. Ayvazyan A.V. Vardevanyan G.G. Avagyan E. S. Harutyunyan V. A. Successful treatment of multiple fractures of the lower extremities due to polytrauma. // Journal of Polytrauma. No. 3 [September] 2010.P.66.70
5. Mezhebityskaya L.O. Trofimova E.Yu. Byalik E.I. Semenova. M.N.
6. Frequency and timing of detection of thromboembolic complications during dynamic ultrasound angioscanning in patients with polytrauma. Journal Polytrauma. 2009 No. 2. P. 48.54.
7. Apaguni A.E. Errors and complications of surgical treatment of diaphyseal fractures of the femur // *Travmatol. and orthopedist. Russia.* – 2005. – No. 1 (34). – pp. 38-39.
8. Mattis E.R. System for assessing the outcomes of fractures of the musculoskeletal system and their consequences: Abstract of thesis. dis. ...Dr. med. Sci. – M., 1985. – 29 p.
9. Pankov I.O., Sirazitdinov S.D. Fat embolism syndrome as the main cause of mortality in severe polytrauma // *Sovrem. problem science and education.* – 2015. – No. 2 (58). – pp. 12-18.
10. Pashchuk A.Yu., Fadeev P.A. Diagnosis and treatment of fat embolism // *Orthopedist. traumatol. and prosthetics.* – 1991. – No. 12. – pp. 41-42.
11. Pronskikh A.A. Tactics for treating injuries to the musculoskeletal system in patients with polytrauma // *Polytrauma.* – 2006. – No. 1. – pp. 43-47.
12. Sokolov V.A. Prevention and treatment of complications of polytrauma in the post-resuscitation period // *Vestn. traumatol. and orthopedist.* – 2002. – No. 1. – pp. 78-84.
13. Sokolov V.A., Byalik E.I., Fain A.M. and others. Prevention and treatment of complications of closed locked osteosynthesis of long bone fractures in patients with polytrauma // *Vestn. traumatol. and orthopedist.* – 2008. – No. 2. – pp. 29-32.
14. Shapkin Yu.G. Seliverstov P.A. Efimov E.V. Surgical tactics for polytrauma with damage to the musculoskeletal system.//*Polytrauma.* No. 4 [December] 2014 P.82.88.
15. Shukurov E.M. External fixation devices in the treatment system for multiple fractures of the bones of the lower extremities // *Genius of Orthopedics, Kurgan, Russia, 2011.-No. 4.-P.9-13 (14.00.00, No. 39).*
16. Shukurov E.M. Modern aspects of the treatment of patients with multiple fractures of the bones of the lower extremities (Literature review) // *Genius of Orthopedics, Kurgan, Russia, 2014.-No. 3.-P.89-93 (14.00.00, No. 39).*
17. Shukurov E.M., Kasimova G.T., Akhmadzhonov O.N. Treatment and prevention of thrombosis and thromboembolic complications in patients with fractures of the long bones of the lower extremities // *Journal of Theoretical and Clinical Medicine, 2014.-No. 2.-P.-113-117 (14.00.00; No. 3).*
18. Kim J., Khavanin N., Rambachan A. Surgical duration and risk of venous thromboembolism // *J.A.M.A. Surg.* – 2015. – Vol. 150, №2. – P. 110-117.

