

The Effectiveness of Subintimal Balloon Angioplasty in the Treatment of Critical Lower Limb Ischemia in Patients with Diabetes Mellitus.

Sattarov I.S., Matmurotov K.Zh., Yakubov I.Y., Rakhimov D.J

The aim of the study is to present the immediate and long-term results of treatment of patients with diabetic foot syndrome using subintimal balloon angioplasty.

Materials and methods of research. 38 patients with ischemic and neuroischemic forms were under observation. All were with type 2 diabetes mellitus and over the age of 60. Diabetic foot syndrome complicated by a purulent-necrotic process. 2 groups were identified: the first control group (20 people) received traditional treatment and the second group (18 people) who underwent balloon angioplasty.

The results of the study. According to the main clinical indicators, both groups were equivalent, and both groups received medication in equal volume, and only in the main group treatment was supplemented with subintimal balloon angioplasty of the arteries of the lower extremities. When analyzing the immediate and long-term results of both groups, a more favorable course was found in patients of the second group, which was characterized by faster wound cleansing, the appearance of granulations and epithelizations and a reduction in the duration of inpatient treatment. The results of observations for 2 years showed that the recurrence of ulcers in patients of the control group was in 6, and mainly in 2. The results obtained allow us to note a more favorable course of SDS when using subintimal balloon angioplasty.

Keywords: diabetes mellitus, diabetic foot syndrome, subintimal balloon angioplasty.

Relevance. Diabetes mellitus (DM) is one of the main health problems of the 21st century. The number of patients with diabetes has been steadily increasing over the past three decades, and this growth is likely to continue over the next decades: from approximately 463 million patients aged 18 to 99 years in 2019 to approximately 700 million people of the same age group in 2045 worldwide [2,9].

One of the most frequent complications of diabetes mellitus is diabetic foot syndrome (DFS), the frequency of which ranges from 15-35%, and the neuroischemic and ischemic form among patients with DFS is 70-75% with the formation of wet and dry gangrene, trophic and purulent-necrotic changes in the soft tissues of the foot [1,5,10]. The urgency of this problem is due to the high frequency of amputation of a limb or foot and the associated risk of severe complications, the treatment of which, especially with necrotic complications, is complex and not always satisfactory.

In the treatment of this complication, many medications, physical factors, and their combinations have been proposed, but often the disease progresses and a high amputation of the limb is performed, and often after amputation of one limb, a process occurs on the second, which also leads to amputation. [4,7,11].

Diabetic foot syndrome is currently considered as the most severe of all late complications of diabetes mellitus. Diabetic foot ulcer, gangrene and performed amputation cause the highest damage to health, reduce the quality of life of patients and are accompanied by significant economic costs [1,6,9].

Diabetic foot syndrome refers to infection, ulcer and/or destruction of deep tissues associated with neurological disorders and a decrease in the main blood flow in the arteries of the lower extremities of varying severity. Timely diagnosis and treatment of diabetic foot syndrome make it possible to avoid the spread of infection leading to limb amputation and mortality [3,8].

With the development of endovascular technologies, it became possible to improve the blood supply to the soft tissues of the extremities and prevent high amputation. In this regard, a balloon angioplasty technique is proposed, which allows restoring blood flow in 1, 2 and even 3 arteries.

The aim is to present the immediate and long-term results of treatment of patients with diabetic foot syndrome using subintimal balloon angioplasty.

Material and methods of examination

There were 18 patients with SDS who underwent subintimal balloon angioplasty (main group) and 20 who received traditional SDS treatment (control group). Of the 38 patients, there were 12 women (31.5%), 26 men (68.5%). The age ranged from 60 to 84 years, in general, the age was 68.2 ± 6.1 years. Everyone had type 2 diabetes. The duration of diabetes ranged from 5 to 25 years, but in most (23 people) the duration of the disease exceeded 15 years. Of the 38 patients, 12 (31.5) had ischemic form of SDS, and 26 had neuroischemic form (68.5). 13 (34.2%) patients had ischemic trophic ulcer, and 25 had gangrene of the 1st and 2nd fingers (65.8%). According to the based clinical indicators, both groups were equivalent, and both groups received medication in equal volume, and only in the main group treatment was supplemented with subintimal balloon angioplasty of the arteries of the lower extremities.

Upon admission, in addition to general clinical examinations, ultrasound Dopplerography (UZDG), ultrasound duplex scanning and multispiral computed tomography (MSCT) were detected arteries of the lower extremities, which makes it possible to determine the extent and nature of vascular lesions.

Medical and surgical treatment was carried out in the department of purulent surgery and surgical complications of diabetes mellitus at the multidisciplinary clinic of the Tashkent Medical Academy.

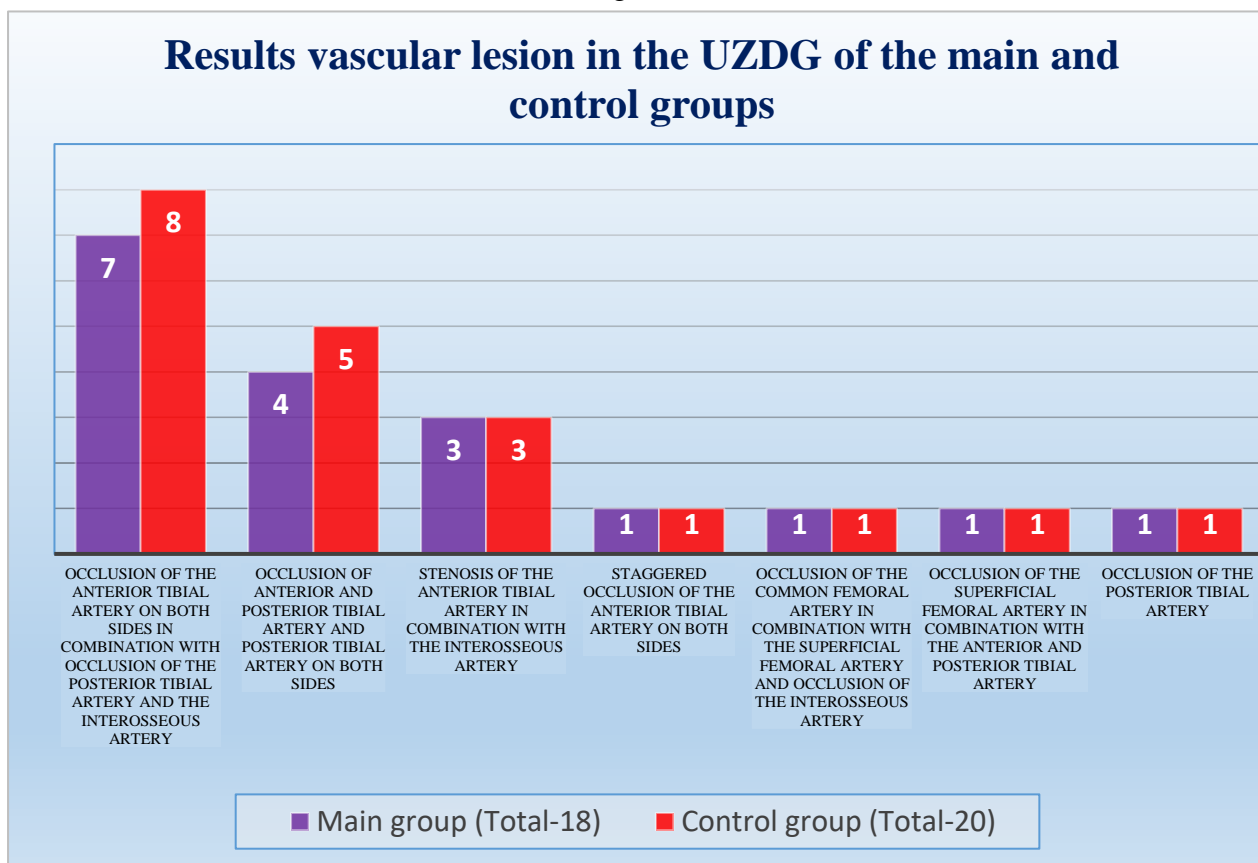
Statistical data processing was performed using applied computer programs for statistical processing of the DBASE and STAT4 databases. For calculations, statistical methods were used to estimate differences in average values using the Student's t-test.

Results and their discussion.

As a result of the application of a complex of research methods using ultrasound, Dopplerometry and ultrasound duplex scanning, from among the patients we observed (108 people), 18 had vascular patency disorders, of which men - 14, women - 4. The age was from 60 to 84 years (68.2 ± 5.2 years). The term of diabetes mellitus in the majority exceeded 15 years. The ischemic form of SDS was detected in 6 and neuroischemic in 12. For 3-4 days, they underwent hypoglycemic therapy and treatment of concomitant diseases, and local treatment of purulent-necrotic complications, and then balloon angioplasty. Patients of the main group due to total occlusion of peripheral arteries in the planning of revascularization surgery initially decided to perform subintimal balloon angioplasty due to the impossibility of transluminal balloon angioplasty and to prevent relapses in the immediate postoperative period. According to the results of the USDG study of peripheral artery lesions in the studied groups were homogeneous and the examined patients were statistically comparable.

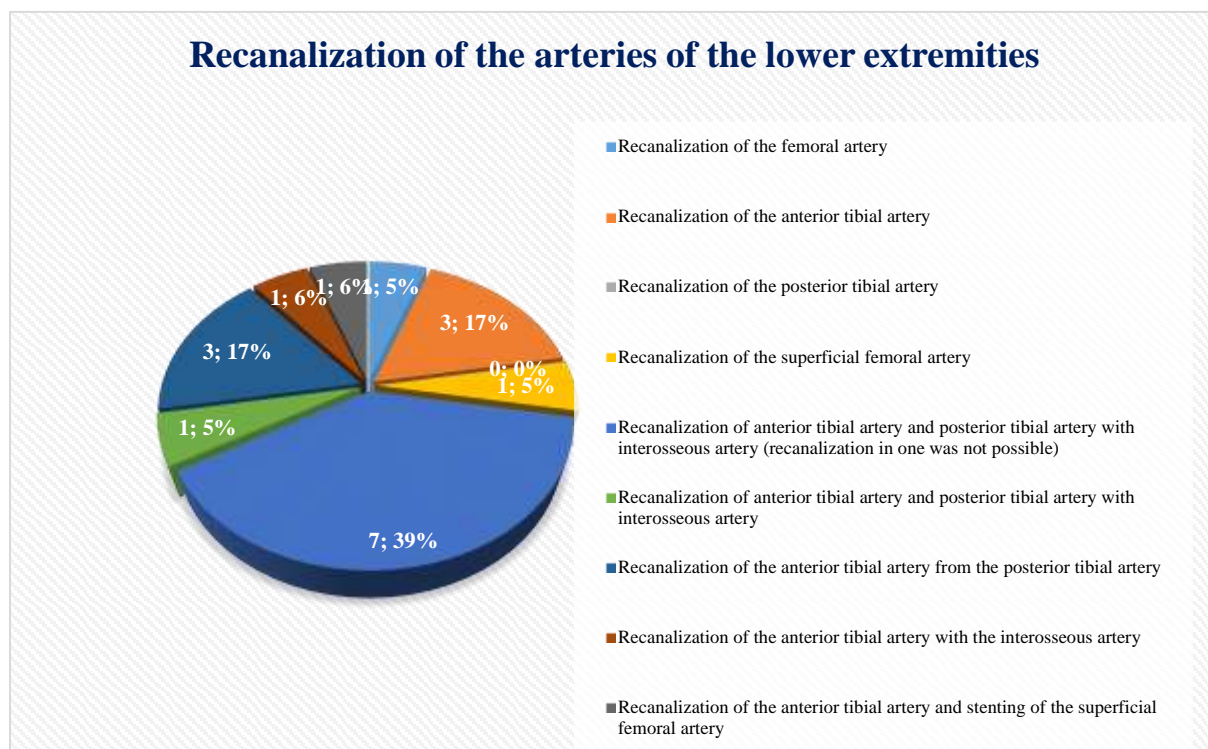
As a result of a comprehensive examination, the following changes in the vessels of the lower extremities were revealed (fig. 1.).

Diagram 1.



Angiography of the lower limb was performed before and after angioplasty. The first stage was puncture and catheter insertion, then a guide was carried out beyond the vascular lesion zone to provide balloon angioplasty, the balloon was opened at different levels of the arteries and completed with a control angiography to assess the patency of the vessels. We did not observe any complications during subintimal balloon angioplasty. In our study, all patients had lesions (total occlusions) of the lower leg arteries, which in most cases were combined with Menkeberg's mediocalcinosis. This situation made our surgical treatment tactics much more complicated, since in many patients, despite the restoration of arterial inflow of the main blood supply type, the expected result was not achieved due to a violation of blood outflow. The number of recanalizations of individual vessels is given in Diagram 2.

Diagram 2.



After angioplasty, oxygen saturation of soft tissues was determined and a positive result was obtained. Before angioplasty oxygen saturation was $70.4 \pm 2.18\%$ and after angioplasty $86.4 \pm 2.37\%$, the differences are significant ($P < 0.001$)

It should be noted that the treatment of both groups included hypoglycemic drugs, anti-inflammatory and infusion therapy, anticoagulants and local treatment of wounds under a bandage. The patients had wounds of various sizes and depths. The depth of the wound process was classified according to Ahrenholz (1989) and consequently local dressings were started depending on the phase of the wound process. We also followed the course of the wound process and compared it with the results of the control group (Table 1).

Table 1.
 Indicators of the course of the wound process in patients
 of the control and main groups

Indicators	Main group $M_1 \pm m_1$	Control Group $M_2 \pm m_2$	P-degree confidence $M_1 - M_2$
The disappearance of edema	$3,1 \pm 0,19$	$4,5 \pm 0,13$	$<0,05$
Cleansing the wound	$4,1 \pm 0,17$	$5,8 \pm 0,18$	$<0,01$
Appearance of granulations	$6,8 \pm 0,11$	$8,2 \pm 0,21$	$<0,01$
The appearance of epithelization	$8,2 \pm 0,13$	$9,4 \pm 0,17$	$<0,05$
Terms of inpatient treatment	$14,7 \pm 0,27$	$18,8 \pm 0,27$	$<0,001$

* the indicators of the wound process were calculated from the beginning of treatment after angioplasty and the control group from the moment of treatment.

Analysis of the course of the wound process allowed us to note more favorable results at an earlier

date in patients who underwent subintimal balloon angioplasty.

For two years, along with the assessment of the condition of patients, under our control, patients performed preventive treatment courses to prevent the recurrence of trophic ulcers.

We have studied the results after angioplasty for two years. So, in the main group, after 6 months, 1 patient had a recurrence of the ulcer, a year later another 1 had a recurrence of the ulcer, and one had an amputation at the level of the upper third of the lower leg due to the progression of the purulent-necrotic process, and 2 had a repeated violation of the patency of the popliteal artery, they performed repeated balloon angioplasty, the condition improved.

After 2 years, 15 patients were examined, of which no recurrence of ulcers was found. During the entire follow-up period, 2 patients died from diseases unrelated to SDS, from acute myocardial infarction.

Analysis of the results of patients in the main group showed that the recurrence of ulcers was detected in two. During the control examination, two patients were found to have a violation of vascular patency, they underwent repeated balloon angioplasty.

Examination of patients in the control group showed: after 6 months, a recurrence of the ulcer occurred in two, and one had a high hip amputation due to the progression of the purulent-necrotic process, and the rest remained stable. A year later, 2 ulcers relapsed, and one had necrosis of the fingers. After 2 years, 2 more have a recurrence of ulcers. During the period (2 years), 2 patients died (both from stroke). Thus, in the control group of 20 patients, 6 relapsed at various times, one had a high hip amputation, and two died from diseases unrelated to SDS. Timely and correctly chosen surgical tactics are the key to favorable results. In the future, in surgical practice, attention should be paid to preventive operations on peripheral arteries and to develop clinical aspects of predicting the development of vascular complications in patients with SDS.

Conclusions.

1. Subintimal balloon angioplasty of peripheral arteries improves the course of critical ischemia of the lower extremities against the background of diabetes mellitus, this is more significantly expressed in the immediate results, and in the period up to 2 years, the indicators of the course of the disease are better than in the control group.
2. All patients with SDS need to perform duplex scanning to detect arterial hemodynamic disorders and timely perform subintimal balloon angioplasty as a method to improve the course of the disease.
3. The preservation of a supporting lower limb with the help of an adequately selected revascularization technique (subintimal balloon angioplasty) is the main goal for gangrene of the lower extremities, which directly affects the quality of life and such tactics gives a high chance for patients to maintain their social status in society.

List of used literature.

1. Avdovenko A.L. Differentiated approach to the treatment of diabetic foot /A.L. Avdovenko, V.P. Sazhin, V.N. Emkuzhev// Standards of diagnosis and treatment in purulent surgery - M., 2011. - pp. 72-73.
2. Bulavkin, V.P. Revascularization in the complex treatment of purulent-necrotic forms of diabetic foot /V.P. Bulavkin, A.P. Kutko, A.A. Tretyakov// Achievement of fundam., wedge. medicine and pharmacy: Materials of the 65th scientific session of the sec. University. - Vitebsk. VSMU, 2010.- pp. 15-17.
3. Galstyan, G.R. Diseases of the arteries of the lower extremities in patients with DM: Condition, problems and prospects of treatment /G.R. Galstyan, A.Y. Tokmakova, O.N. Bondarenko // Diabetes mellitus.- 2011.- No. 1.- pp. 10-15.
4. Gavrilenko, A.V. Surgical treatment of critical lower limb ischemia in patients with DM /A.V. Gavrilenko, A.E. Kotov, D.A. Lonkov// Annals of Surgery.- 2012.-
5. Dedov, I.I. Diabetic foot /I.I. Dedov, O.V. Udovichenko, G.R. Galstyan. - M.: Prakt. Medicine, 2005.- 197 p.
6. Zholdosbekov, E.J. Diabetic foot syndrome (clinic, diagnosis, treatment) / E.J. Zholdosbekov. - Bishkek: LLC "Kut Ber", 2012.- 168 p No. 2.- p. 10-15.

7. Kalinin, A.P. Diabetic foot /A.P. Kalinin, D.S. Rafibekov, M.I. Akhunbayev. – Bishkek, 2000.- 286 p.
8. Kaputin M.Yu., Ovcharenko D.V., Platonov S.A., Chistyakov S.P. Comparative analysis of long-term results of transluminal balloon angioplasty in the treatment of critical lower limb ischemia in groups of patients with and without diabetes mellitus. *Angiol and the vessel hir* 2010; 16: 3:41-46
9. Kisses, D.D. Endovascular methods in the treatment of critical lower limb ischemia and diabetic foot syndrome / D.D. Kisses, S.E. Tursynbayev, A.E. Asylbekov// *Bulletin of Kaz NMU.*- 2018.- №4 (2).- Pp. 299-300.
10. Lepantalo, M. Peripheral artery diseases in patients with diabetes mellitus with renal insufficiency: review /M. Lepantalo. Lepantalo, L. Fiengo, F. Biancan// *Diabetes. Metal. Ed.*- 2012.- No.28.- pp. 40-45.
11. Pierret K., Tourtier J.P., Bordier L., Pancake E., etc. Subintimal angioplasty and revascularization of diabetic foot. *Presse Med* 2011; 40:1, Part 1: 10-16.