

Possibilities of Transperineal (Transperineal) Echography in The Diagnosis of Prostate Diseases

Umurzakov Akmal Ismailovich,
Azizov Gafur Abdurakhimovich

Andijan State Medical Institute
Andijan. Uzbekistan

Assistant of the Department of Medical Radiology
Assistant of Department 1-Faculty and Hospital Surgery

Annotation: The possibilities of transperineal (transperineal) ultrasonic examination of the prostate gland in it is various pathological conditions were investigated. The analysis included ultrasound data of 92 male patients with various pathologies of the prostate gland in the period from 2018 to 2022. Patients underwent an ultrasound examination of the pelvic organs, including a transabdominal examination and, subsequently, a transperineal examination. Transabdominal examination was not possible in the presence of a postoperative wound, after surgery on the bladder, the presence of drainage, inflammation in the suprapubic region, the patient's obesity, and the presence of flatulence. Empty or empty bladder due to bladder failure. A large body weight and a large fat layer on the abdomen also made it difficult to examine the prostate gland. A visual comparison of the transabdominal and transperineal ultrasound methods for examining the prostate gland in its various pathological conditions is presented.

Key words: prostate gland, transperineal sonography.

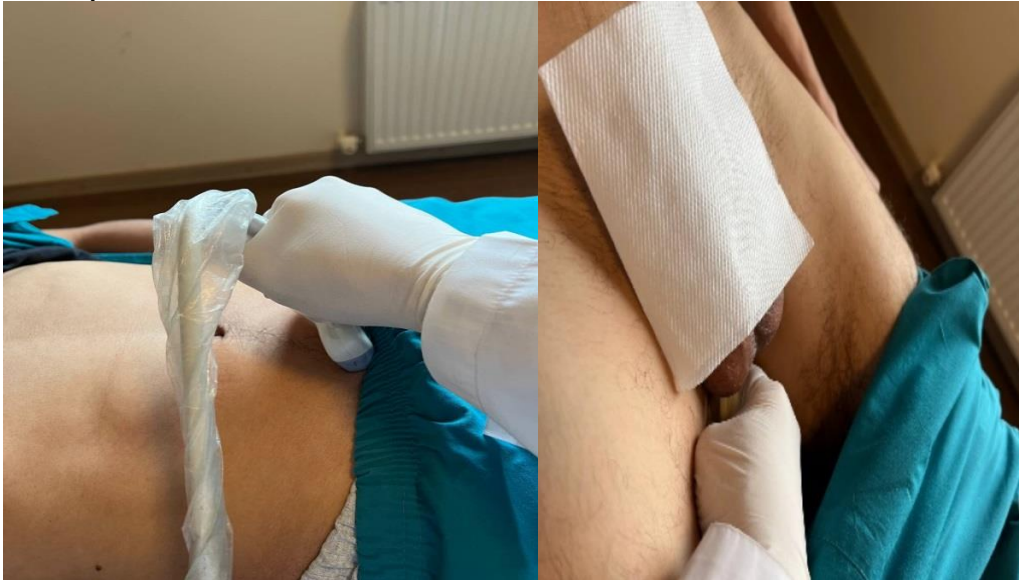Introduction, Ultrasound examination is the leading method of diagnosing prostate diseases. It is successfully used as a screening, widely used in puncture and aspiration biopsies; as well as as a means of controlling the treatment of inflammatory diseases of the prostate, benign and malignant prostatic hyperplasia. With the advent of such techniques as color and energy Doppler mapping, tissue harmonics, three-dimensional echography and three-dimensional angiography, echocontrast angiography, diagnosis of prostate diseases has moved to a new level. With the help of new ultrasound technologies for imaging the prostate gland and its vascular structures, it has become possible to carry out high-precision diagnostics of the earliest forms of diseases and monitor treatment. As a screening for the detection of prostate pathology, it is recommended to use echography in persons with prostate diseases — due to the high prevalence of inflammatory diseases and prostatic hyperplasia and diseases of the pararectal fiber. Echographic methods of prostate examination are: usually transabdominal and transrectal. Contraindications to transrectal examination are diseases of the rectum (cracks, tumors. hemorrhoids, etc.). Patients with religious prejudices (transrectal study). Transabdominal examination is not possible in the presence of a postoperative wound, after surgery on the bladder, the presence of drains, inflammatory processes in the suprapubic region, obesity of the patient, the presence of flatulence. An emptied or empty bladder due to the failure of the bladder. A large body weight and a large fat layer on the abdomen make it difficult to examine the prostate gland. In such cases, there is a possibility of a trans-interventional examination of the prostate gland.

Currently, the available work on ultrasound transperineal diagnostics does not provide a full opportunity to conduct this examination. There are literature data on research in gynecology and obstetric practice [5,7,8,9,10], coloproctology [1,3,4,6] and also in urology [2].

The aim of the study is to study the possibilities of perineal ultrasound examination of the prostate gland in various pathological conditions.

Material and methods of research. The analysis includes ultrasound data of more than 92 male patients with various prostate pathology in the period from 2018 to 2022. All patients underwent ultrasound examination of the pelvic organs, including transabdominal examination and, subsequently, a trans-interventional examination. Ultrasound examination was performed on Samsung Medison Accuvix V10 devices (Yu .Korea), Philips Affiniti 30 (USA-Netherlands) GE logiq P9 (USA) with convexic sensors operating in the

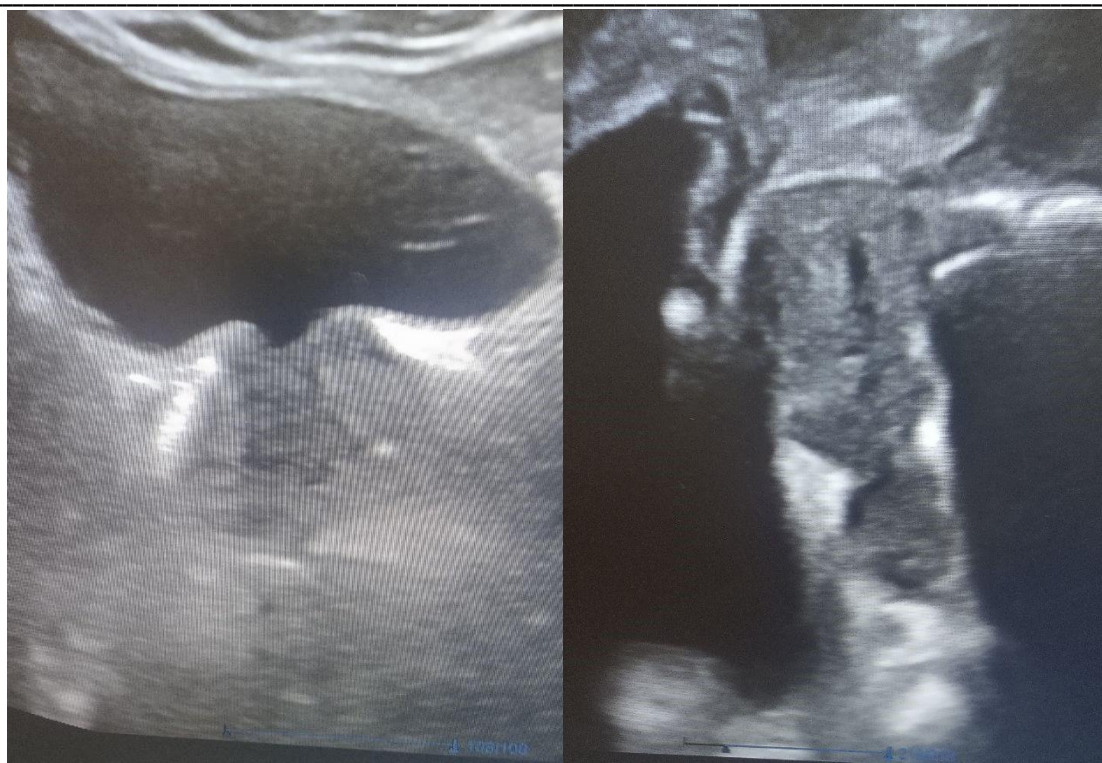
3.5-7 MHz frequency range. The average age of the patients was 48 ± 6 years (from 27 to 75 years); With echography, the size of the gland, the condition of the capsule, focal changes in the gland tissue, the course of the urethra and paraurethral space were determined. The size and structural changes of adenomas and hyperplasias of unclear etiology requiring histological analysis. All patients were initially examined in the supine position with their legs spread apart. Any non-sterile rubber glove with gel application on the outer and inner surfaces is put on the convex sensor.



Abdominal Through Perineal
Figure 1. Research methodology

The results of the study and their discussion.

An analysis of the results of a comprehensive ultrasound examination of 20 practically healthy men showed that, normally, with trans-intervertebral echography, the prostate gland is located at the base of the bladder, to the front of the rectum and is visualized in the sublobular longitudinal sections. Normally, the size of the prostate gland did not exceed 26mm x 31 x mm x 29mm, and the volume was from 19 to 26 grams. In older men, the anthropometric data exceeded this norm. Figure No. 2 shows the abdominal and trans-interventional method of examining the prostate gland in healthy individuals. As can be seen with the transabdominal method, it is not possible to fully visualize the located areas of seals along the urethra. However, the location of the compacted zones relative to the course of the urethra was clearly differentiated during the trans-interventional study.

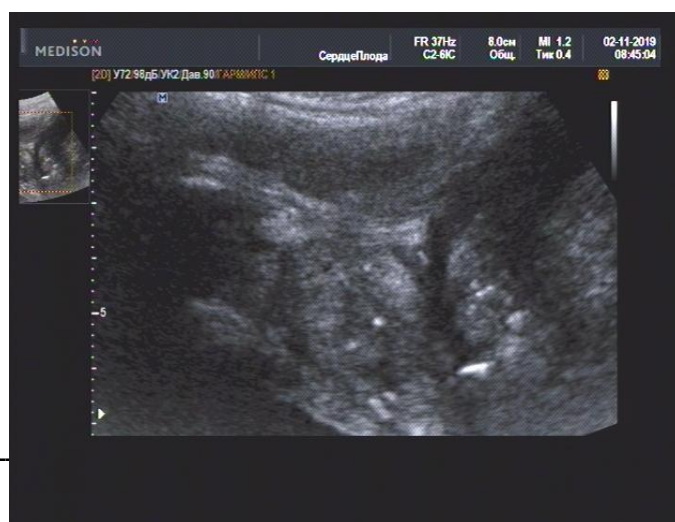
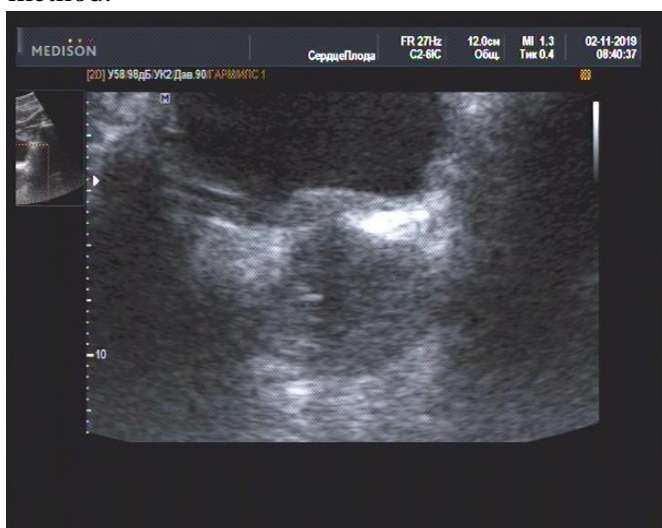
Abdominal Through perineal

Fig. 2 prostate gland in transabdominal and transperineal examination in a healthy person.

32 patients with inflammatory processes in the prostate gland were examined. Thus, acute bacterial prostatitis was clinically manifested by various dysuric phenomena, pain and discomfort in the perineum, pain during defecation in 3 patients with septic phenomena. The diagnosis is traditionally established on the basis of clinical symptoms and characteristic palpatory changes (with rectal finger examination, an enlarged, edematous, sharply painful gland is determined). In practice, there have been cases of diagnostic error due to the similarity of clinical symptoms of acute prostatitis and acute paraproctitis. However, ultrasound examination helped to solve this diagnostic problem. Ultrasound examination at the stage of edema and infiltration of the gland revealed: enlargement of the gland, a change in its shape (the gland becomes spherical), a change in the structure of the gland, while significantly reducing the echogenicity of the gland, the echographic differentiation of glandular and fibromuscular tissues was lost.

Here is an example of a patient with inflammatory processes (acute prostatitis) in the prostate gland. In a patient born in 1978 with the abdominal method of examination (Fig. 3), the dimensions of the prostate gland were enlarged 35 x 28 x 38 mm 28 gy (N 38 x 34 mm), the contours are even and clear, the capsule is clearly differentiated, the edematous form is preserved. Parenchyma is heterogeneous due to foci of microcalcifies with perifocal edema and different echogenicity. In the right lobe there are 2 foci of fibrosis 3.5 and 2 mm. The figure shows that the trans-interventional study gave a higher informative value in the form of multiple foci of micro calcifications and edema zones compared with the transabdominal study method.

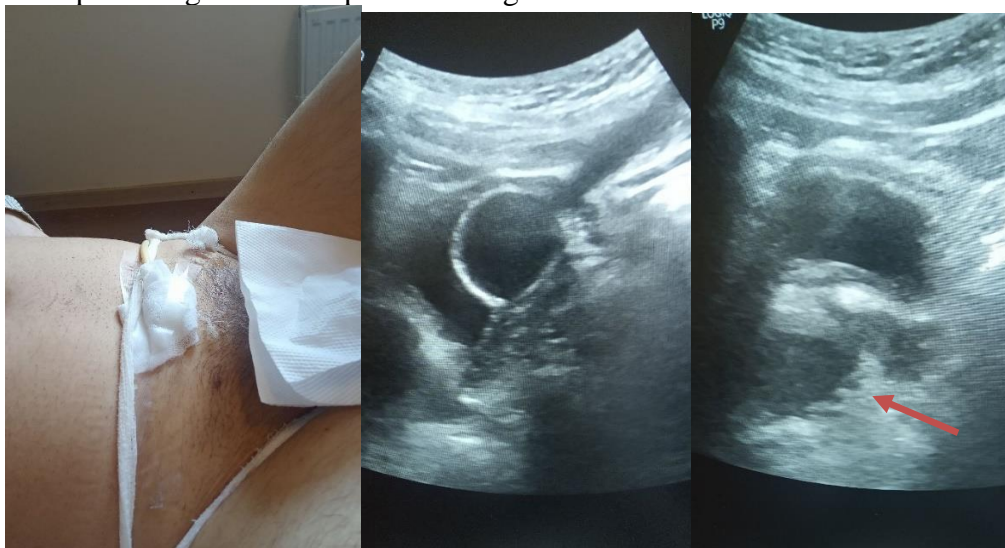

A. transabdominal

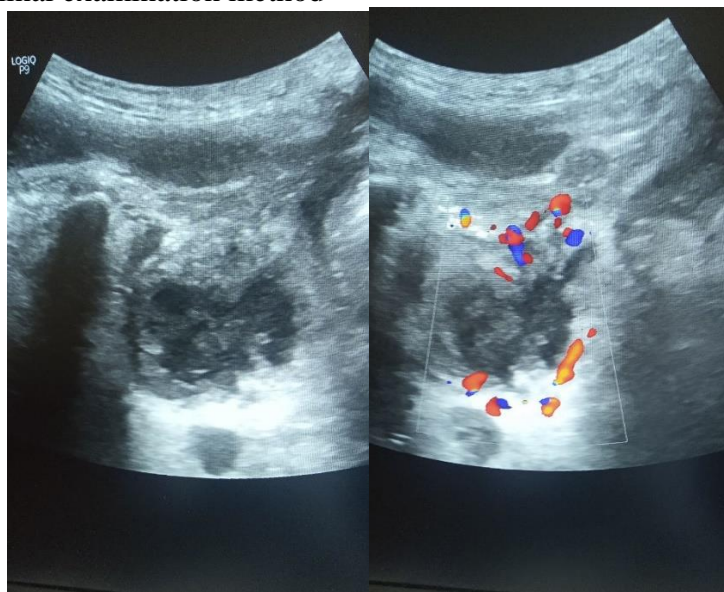
B. trans-interventional examination

Fig.3 Picture of the prostate gland in transabdominal (A) and trans-interventional m (B) examination in a patient with acute prostatitis. With perineal examination, the presence of microcalcifies can be noted.

Example 2. Patient U. born in 1970 with complicated prostatitis with the presence of a closed abscess on the posterior side of the prostate gland in the pararectal region.



A. Traditional abdominal examination method



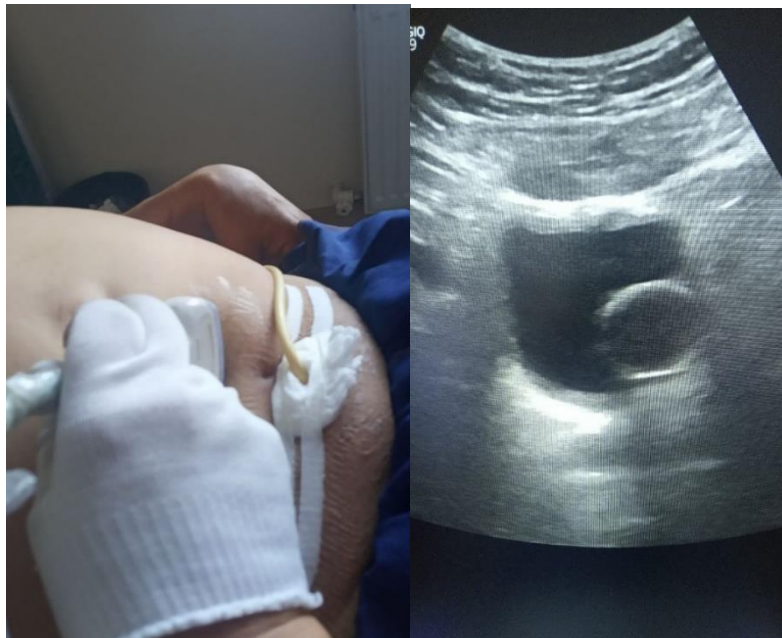
Б. Осмотр через промежность

Fig.3. The picture of the prostate gland in a transperineal examination in a patient with a closed abscess on the posterior side of the prostate gland (in the pararectal region) in the CDC mode, the hypervascularization zone is clearly visible.

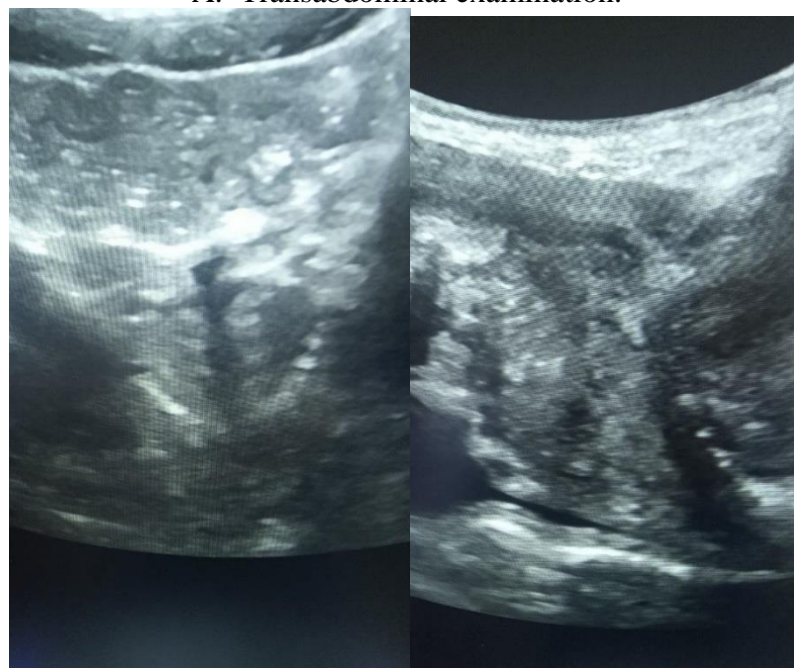
In the study of patients with chronic prostatitis, the size of the gland often remained within the normal range, during the period of exacerbation, the gland increased, in the stage of sclerosis it decreased. The contour of the gland was smooth and equally intermittent, jagged. The echostructure of the gland in the studied 17 patients was practically changed in the form of small foci of microcalcifies and fibrosis zones or by a diffuse increase in echogenicity. At the same time, the heterogeneity of the gland was often revealed in the form of alternating small zones of increased echogenicity in combination with reduced echogenicity, as well as with the presence of anechoic zones.

Example 3. A patient with chronic prostatitis.

Patient M., born in 1972, Prostate gland: Dimensions 35 x 28 x 38 mm 19 gr (N 38 x 34 mm), not enlarged, contours are even and clear, the capsule is clearly differentiated, the shape is preserved. Parenchyma is heterogeneous due to multiple foci of microcalcinates, increased echogenicity. In the right lobe, the focus of fibrosis is up to 5-6 mm. In Figure 4, with an incomplete bladder (bladder volume of 100 ml.), transabdominal examination did not give a complete picture of the inflammatory process of the prostate gland. Perineal ultrasound revealed a clear visualization of the sealing zone along the urethra in the prostate gland



A. Transabdominal examination.



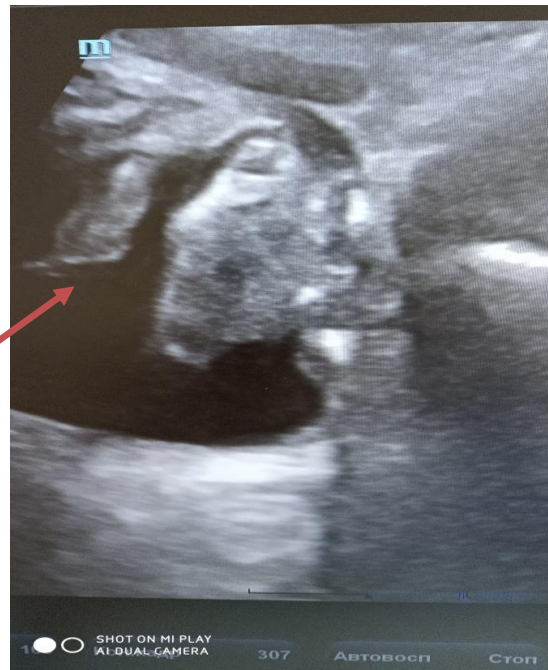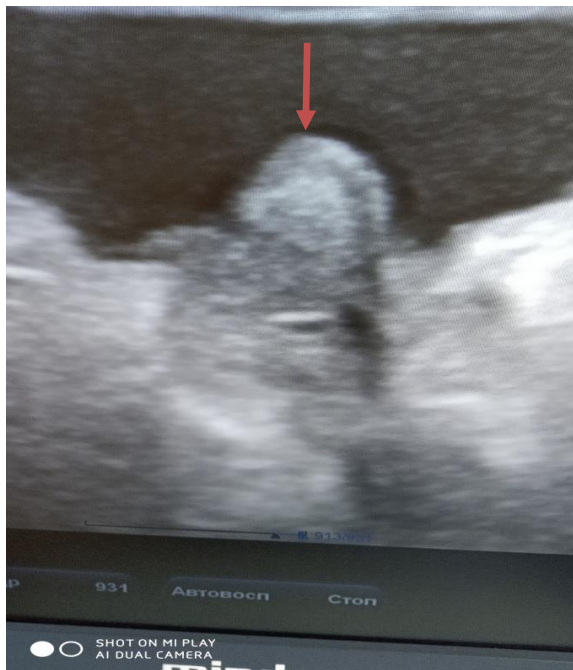B. A trans-boundary study

Fig. 4. The picture of the prostate gland during transabdominal and trans-interventional examination in a patient with chronic prostatitis at the last fibrosis zone is clearly differentiated.

39 patients with benign prostatic hyperplasia were examined. Clinical manifestations in this category of patients were characterized by increased urination, nocturia, weakening of the pressure of the urine stream during urination, slowing urination. Benign prostatic hyperplasia during sonography in this category of

patients usually manifests itself as a limited or diffuse increase in the periurethral gland in the area of the bottom of the bladder (an increase in the average lobe of the gland with smooth edges and a normal capsule of the gland).

Here is an example of a patient with benign prostatic hyperplasia. Patient M 1952.p. Prostate gland: dimensions: width 51 mm thickness 42 mm length 48 mm 55 gr (N 38 x 34 mm), enlarged, contours are not even clear, the capsule is clearly differentiated, the shape is not preserved. The parenchyma is heterogeneous, with increased echogenicity. The right lobe of the vesicular part is an adenoma of 25 x 15 mm. Left lobe - adenoma 28 x 16 mm along the lateral wall fibrosis 18 x 8 mm. Bubble growth is 22 mm. Microcalcinates along the urethra (Fig. 5).

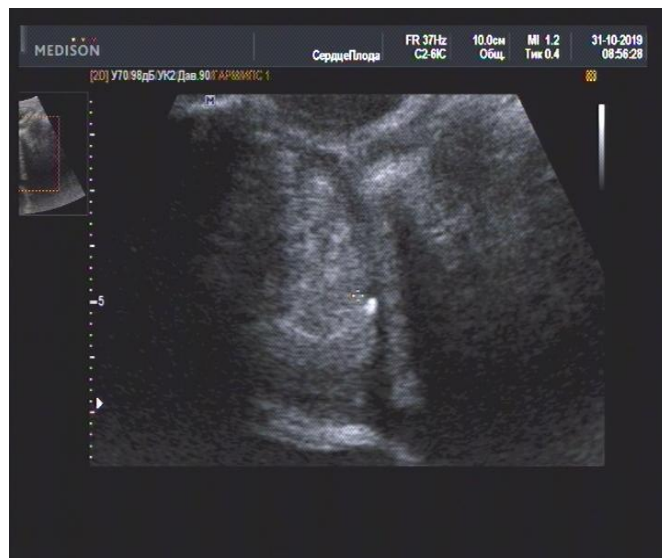
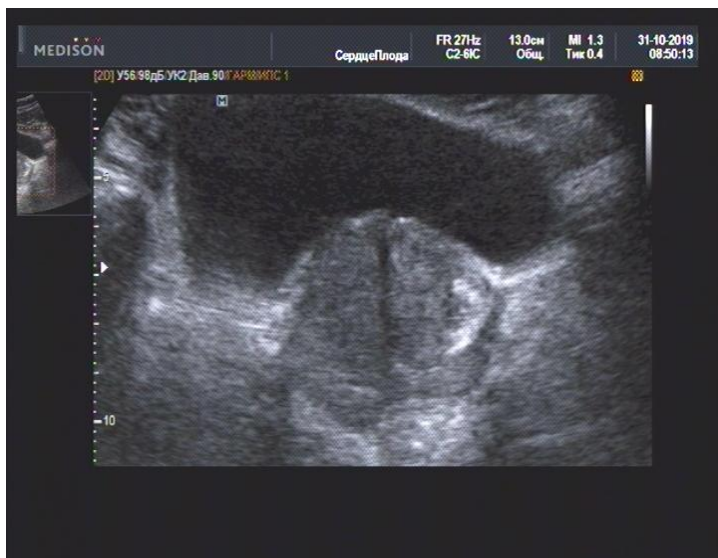
Transabdominal examination

Trans-interventional examination

Fig.5. When comparing, it is seen that during a trans-interventional examination, a more detailed image of the prostate adenoma is its deformed course of the urethra as well as multiple areas of compaction in the thickness of the prostate gland, combined with cystic destruction (see arrows).

Here is an example of a study of a patient with a diffuse form of prostate adenoma. Patient D 1950g.r. Prostate gland: dimensions: width 58 mm thickness 62 mm length 60 mm 110 gr enlarged, contours are uneven clear, the capsule is clearly differentiated, the shape is hemispherical.

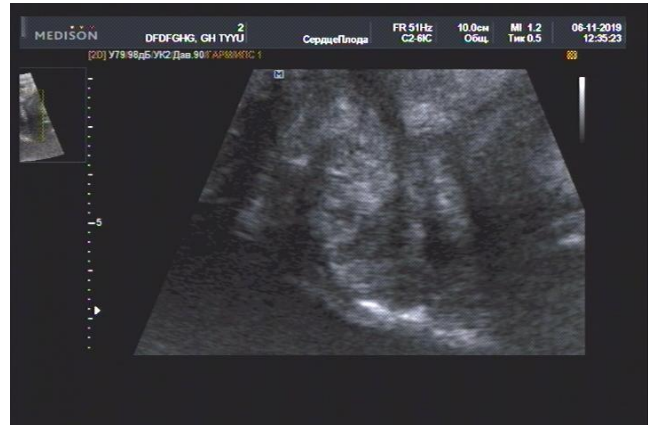
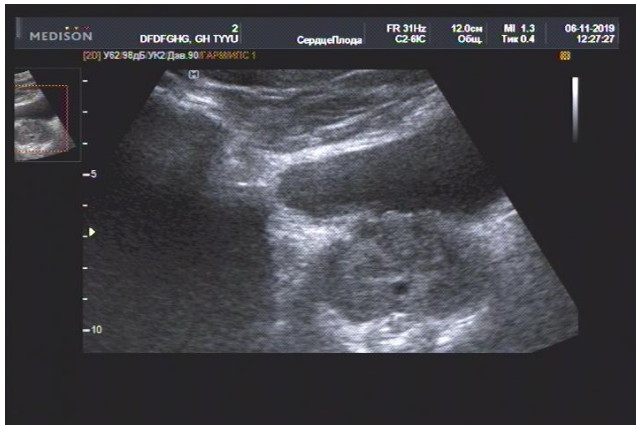
Transabdominal examination

Trans-interventional examination

Fig.6. Picture of transabdominal and trans-interventional examination in a patient with benign prostatic hyperplasia. Calcinate is visualized in a transpermediation study.

Imagine a patient with a prostate cyst. A patient from 1961 was examined with the phenomena of chronic nonspecific colitis, an ultrasound examination revealed a prostate cyst.



transabdominal

trans-interventional study

Fig.6 Picture of a patient with a prostate cyst

Here is an example of a patient with the presence of a fistula. Patient Yu 1965 p prostate gland dimensions 43 x 44 x 46 mm 45 gr. enlarged, the contours are even clear, the capsule is clearly differentiated, the shape is preserved. The parenchyma is heterogeneous, with increased echogenicity. In the right lobe, fibrosis is 18 mm. In the left lobe, fibrosis is 28 x 18 mm . The right lobe is a 10 x 10 mm cystic cavity along the periphery of the 7-8-12 mm fibrosis zone with microcalcifies

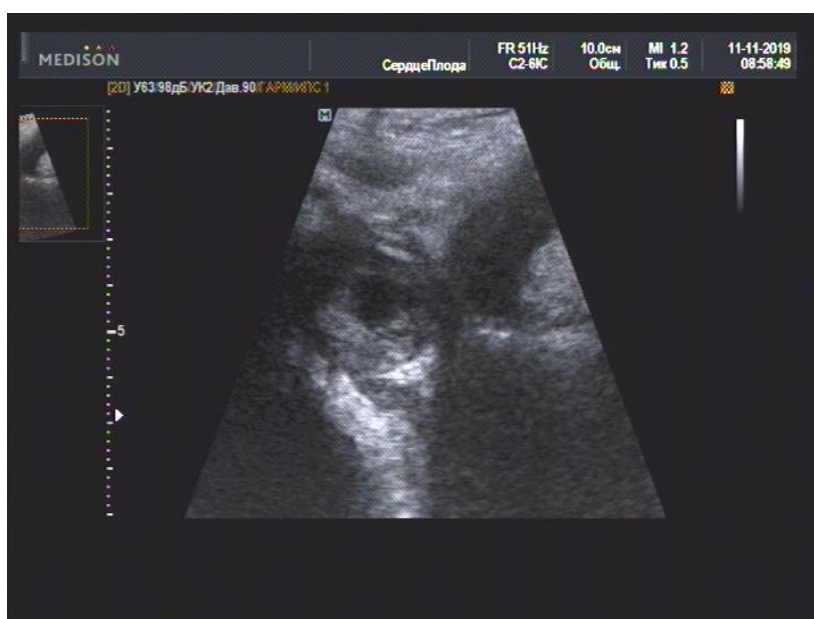

Fig.7 The picture of a transperminisitional examination of a patient with the presence of a fistula. Signs of chronic prostatitis with the presence of a cystic cavity communicating with the rectum along the posterior wall of the right lobe (fistula).

In the study of patients with prostate formations, the states of the contour (capsule) of the prostate gland were determined, the presence or absence of asymmetric contour deformation was assessed, as well as the clarity of the border between the prostate gland and periprostatic tissue and nearby organs. Asymmetric deformation of the contour of the gland appeared with subcapsular and extracapsular tumor growth. In the study of this group of patients, ultrasound data were compared with the data of finger rectal examination and with the data of laboratory studies (with the level of PSA in the patient's blood serum).

Patient K. 1963 Prostate gland dimensions 56 x 52 x 53 mm 54 gr , enlarged, contours are not even clear, the surface is bumpy, the capsule is clearly undifferentiated, the shape is preserved. Parenchyma is heterogeneous, with different echogenicity. In the central part there is an irregular nodular formation with calcinate 6-7 mm. In the energy Doppler mode, hypervascularization by an irregular curved course of vessels.

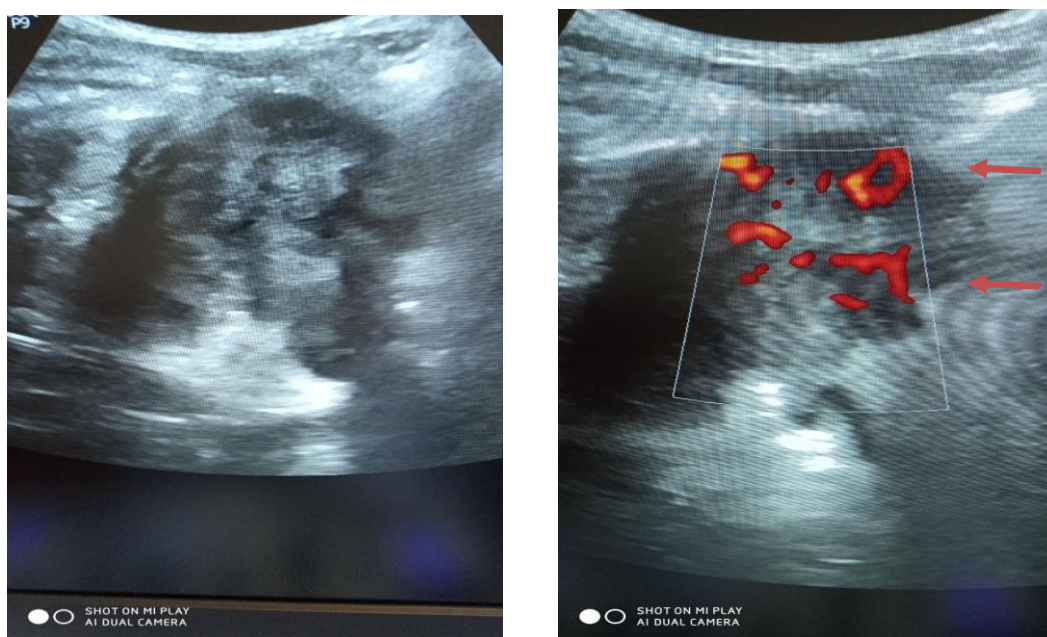


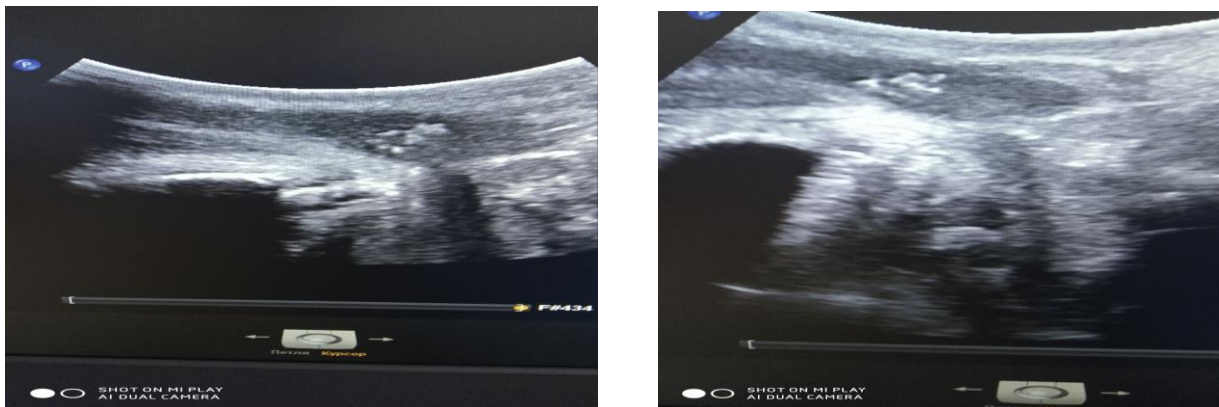
Fig.8 Patient K. The picture through perineal examination of a patient with the presence of education with peripheral growth and hypervascularization.

Below is an example of conducting a transpermanent study of a patient with the presence of a Foley catheter applied against the background of acute urinary retention.

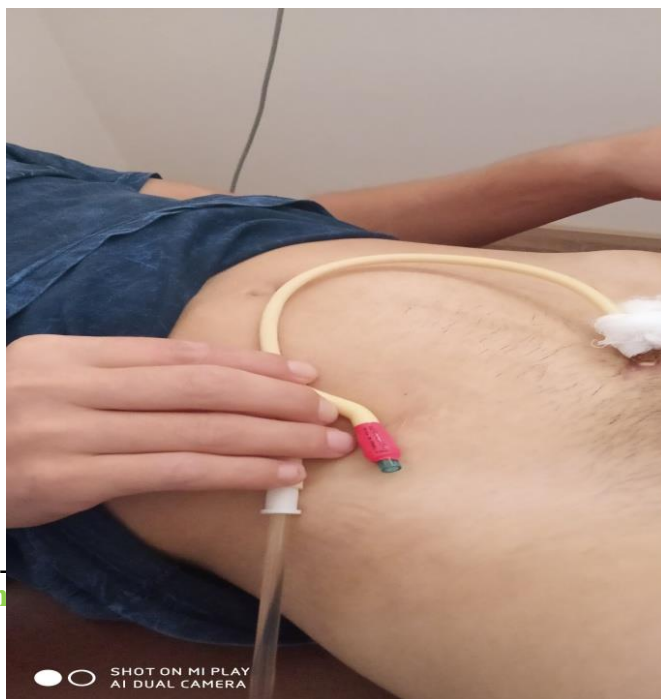

Fig. 10. A picture of a patient with a Foley catheter applied.

When examining a patient with a traditional transabdominal method, visualization of the prostate gland is ineffective (empty bladder). During the interstitial examination, the visualization of the prostate gland and the course of the urethra was optimal and the cause of acute urinary retention was clearly differentiated (a site of accumulation of multiple foci of fibrosis with calcifications at the level of the urethra). For control, a catheter was inserted into the urethra under the supervision of ultrasound. In place of the fibrotic area of the urethra at the base of the penis, the catheter was blocked by stenosis.



trans-boundary study

The results of the study and their discussion. Comparison of the results of the prostate examination by transabdominal and trans-interventional methods with the data of clinical and additional comprehensive instrumental examination confirmed the effectiveness of the trans-interventional study. In all groups of observations, we were able to achieve optimal detail of the echostructure with trans-interminable scanning. It was possible to examine in detail the prostate gland and additionally the rectum with surrounding fiber. In emergency cases, this technique used shortened the examination time of the prostate gland due to the unnecessary filling of the bladder. During the study, there was no psychological and physical discomfort on the part of the patients. This research technique can be used as a screening for the detection of prostate pathology. It is recommended to use echography in people over forty years of age due to the high prevalence of inflammatory diseases, adenoma and prostate cancer. The disadvantage of this study is poor visualization of the entire volume of the bladder (the prostatic part of the bladder is visualized). Thus, trans-interventional echography is an accessible and easily feasible study that allows to identify pathology and determine the local and general prevalence of the pathological process of the prostate gland, and also makes it possible to assess the effectiveness of treatment during monitoring. One of the main advantages of the perineal examination is the ease of execution, the quick ability to obtain clear images and an assessment of the condition that does not require special skills and a lot of time, which is of great importance for use in outpatient and inpatient settings. The use of this method is possible as an addition to traditional studies when making a diagnosis.

List Of Literature:

1. Алиев Э.А.,Ахмедова Э.В. Пропалс тазовых органов Колопроктология №2 (56) 2016стр. 42-47
2. Балан В.Е., Амирова Ж.С., Ковалева Л.А., Ермакова Е.И., Гус А.И., Тихомирова Е.В. Новые возможности ультразвуковой диагностики гиперактивного мочевого пузыря (обзор литературы) // РМЖ. 2016. No 5. С. 318–320.

3. Abdullah A Al Mulhim, Sara L Schulwolf, Kathleen M McFadden, Hamid Shokoohi Transperineal Ultrasound in the Diagnosis of Proctitis in the Emergency Department J Emerg Med. 2021 май; 60(5):e119-e124. doi: 10.1016/j.jemermed
4. Isaid M. Bedair, MD, Hany M. El Hennawy, MD, Ahmed Abdu Moustafa, MD, Gad Youssef Meki, MD, Bosat Elwany Bosat, MD Трансперинеальная анальная сонография сфинктера в комплексной оценке хронических анальных трещин. RH-Узи аппараты,комплектующие,датчики 27.06.2020
5. Гевлргян Д.А., Оразов М.Р., Токтар Л.Р., Хамошина М.Б. Возможности трансперинеальной сонографии в диагностике несостоятельности тазового дна. Трудный пациент №8-9,Том 17,2019стр.20-22. гинекология
6. Hans P Haber¹, Guido Seitz, Steven W Warmann, Jörg Fuchs Transperineal sonography for determination of the type of imperforate anus Am J Roentgenol . 2007 Dec;189(6):1525-9. doi: 10.2214/AJR.07.2468
7. Barbera A., Pombar X., Perugino G., Lezotte D., Hobbins J. A new method to assess fetal head descent in labor with transperineal ultrasound // Ultrasound Obstet Gynecol. 2009. V. 33. P. 313-319.
8. Лологаева М.С.,АрютинД.Г.,Образов М.Р.,Токтар И.Р. Пролапс тазовых органов в ХХІв. Акушерство и гинекология :новости,мнения,обучение.2019/ Т.7, №3. С.76-82 Doi : 10.24411/2303-9698-2019-13011
9. Силантьева Е.С.,Солдатская Р.А.,Оразов М.Р. Белковская М.Э. Трансперинеальная сонография в диагностике несостоятельности тазового дна/ Доктор Ру 2019.№7 (162). С 52-56. DOI: 10.31550)1727-2378-2019-162-7-52-56.
10. Терегулова Л.Е., Мифтахутдинова Д.К., Галимова Э.Р. Ультразвуковая диагностика в родах SonoAce Ultrasound №25,2013 стр 32-36.