

Surgical Treatment of Plantar Fasciitis After failure of Conservative Treatment

1. **Dr. Ammar khayoon Jarallah Alkinany**
M.B.Ch.B \ C.A.B.M.S. (Orthopedic Surgeon)

Iraqi Ministry of Health, Diwaniyah Health Directorate, Ad-Diwaniyah Teaching Hospital, Diwaniyah,
Iraq.
ammarortho74@gmail.com

2. **Dr. Burhanadeen Abdulazez Jabbar Alabudi**
M.B.Ch.B. \ C.A.B.M. (Orthopedic Surgeon)

Iraqi Ministry of Health, Diwaniyah Health Directorate, Ad-Diwaniyah Teaching Hospital, Diwaniyah,
Iraq.
burhanadeenalubudy@gmail.com

3. **Dr. Hassan Ali Shamkhie Aljanabi**
M.B.CH.B. \ C.A.B.M.S. \ (Orthopedic Surgeon)

Iraqi Ministry of Health, Babil Health Directorate, Al-Qasim Hospital, Babil, Iraq.
Hassanorthopedic1977@gmail.com

Abstract

Background: Plantar fasciitis is a common problem faced almost daily in our orthopedic clinic, and it is not easy to satisfy patients with a curative treatment in a short period of time; it is characterized by deep pain in the plantar aspect of the heel, particularly on arising from bed, although the pain often subsides after few steps, in some patients the pain will persist for a long period. **Aim of the study:** To evaluate the result of surgical treatment in cases of plantar fasciitis which are not respond to conservative treatment.

Methods: Prospective study was conducted at the Department of Orthopedic Surgery in Al-Kadhemiyah Teaching Hospital from November 2010 to May 2012 to evaluate 50 patients complaining of inferior heel pain. There were 30 females and 20 males; the main presenting symptoms were pain on the inferno-medial aspect of the heel exacerbating by prolongs weight-bearing and in the morning following sleep.

The age of the patients is 23-58 years. Bilateral heel pain presented in 10 patients in our series; therefore, the overall number of heels treated in our series was 60 heels. All of the patients were treated first conservatively by rest, anti-inflammatory drugs, and local corticosteroid injection. 13 patients showed no response, so we advised them for surgery; 12 patients out of 13 accepted surgery and were treated by plantar fascial release. Patients with systemic diseases had been excluded from our study. **Results:** Regarding treatment, 37 patients (74%) respond to conservative treatment, while 13 patients (26%) had no response to conservative treatment. Therefore they were advised to undergo surgery, and 12 of them accepted surgery. Nine patients (75%) undergoing surgery had a good result (pain-free) 17% of patients undergoing surgery in our study showed fair results (pain after heavy exercise), while 8% showed poor results (persistent pain). Per-operative drilling of calcaneum showed to be effective in post-operative heel pain relieve, which may be due to reduced intra-osseous pressure. Regarding complications, 6% showed superficial wound infection, which was treated conservatively by rest and antibiotics for seven days. Post-operative back slab for two weeks is important to decrease post-operative pain and to facilitate soft tissue healing. **Conclusion:** 1) Complete division of plantar fascia has the advantages of complete relieve of symptoms in 75% of cases of plantar fasciitis, which are resistant to conservative treatment. 2) Drilling of calcaneum had a beneficial effect in postoperative pain relieve by a decrease in the intraosseous pressure. 3) Back slab had a rule in postoperative pain relieve and soft tissue healing.

Keywords: orthopedic, Plantar fasciitis

Introduction

The skin of the sole of the foot is thin on the toes and instep but thick over the heel and ball of the foot (base of the great toe) [1]. The plantar skin contains many sweat glands and much fat in the subcutaneous tissue,

especially over the heel, which is firmly bound down to the underlying structure by fibrous connective tissue; the sole of the foot is designed for weight-bearing and for protection of the underlying nerves and vessels [2]. The sensory nerve supply to the skin of the sole is derived from the medial calcaneal branch of the tibial nerve, which innervates the medial side of the heel, branches from the medial plantar nerve, which innervate the medial two-thirds of the sole, and branches from the lateral plantar nerve which innervate the lateral third of the sole [3,4]. The central portion of the plantar fascia is greatly thickened to form plantar aponeurosis. It consists of a strong thick central part and weaker and thinner medial and lateral parts [5].

The plantar aponeurosis consists of longitudinally arranged bands of dense fibrous connective tissue [6]. The plantar aponeurosis helps to support the longitudinal arches of the foot and to hold the parts of the foot together [7]. It extends anteriorly from the calcaneal tubercles, widens, and diverges into five digital slips which attach to the fibrous flexor sheaths and the plantar metatarsal plate; these plates give the aponeurosis indirect attachment to the bases of all proximal phalanges, providing important support for the longitudinal arch of the foot. The muscles and tendons in the sole are arranged in four layers; the first layer is the important one in the pathology of plantar fasciitis; this layer is called a superficial intrinsic muscle and comprises three muscles which span the length of most of the foot and attach to the deep surface of the plantar aponeurosis p [8,9].

Lies on the medial side and arises from the medial calcaneal tubercle and is inserted to the medial side of the base of the proximal phalanx of the big toe: it is supplied by the medial plantar nerve.

The calcaneum is the largest tarsal bone which forms the prominence of the heel; its long axis is directed forward, upward, and laterally, being roughly cuboidal, it has six surfaces. [10,11]

1. Anterior surface:

It is the smallest surface; it is covered with a concavo-convex sloping articular surface for cuboid bone.

2. Posterior surface:

It is divided into three areas:

A. Upper area is smooth for the bursa.

B. Middle area is rough for the insertion of the tendon-Achilles and p-lantaris muscle.

C. Lower area is rough and sloping; it is covered with dense fibro-fatty tissue and supports the body weight in a standing position

3. Dorsal or superior surface:

Can be divided into three areas:

A. Posterior third area is rough and supports fibro-fatty tissue in front of the tendo-achillis [12,13].

B. Middle third area forms the posterior facet for the talus, which is oval, convex, and oblique.

C. Anterior third area is articular anteromedial and non-articular postern-laterally.

The lateral wider part of the non-articular area provides the origin to the extensor digitorum brevis, attachment to the stem of the inferior extensor retinaculum, and attachment to the stem of the bifurcate ligament. [14,15]

The medial narrow part of the non-articular area forms sulcus calcanei and provides attachment to the interosseous talocalcanial ligaments medially and the cervical ligament laterally.

The articular part of the anterior third area is an elongated facet on the .sustentaculum tali, which may be divided into the anterior and middle facets for the talus.

Is rough and marked by three tubercles.

The medial and lateral tubercles are situated posteriorly, whereas the anterior tubercle lies in the anterior part. Although separated from the anterior border by a roughened depressed area, the medial tubercle is the largest and provides:

a) A. Origin of abductor hallucis medially. [16,17]

b) B. Attachment to flexor retinaculum medially.

c) C. Origin to flexor digitorum brevis anteriorly.

d) D. Attachment to plantar aponeurosis anteriorly.

The lateral tubercle gives origin to abductor digitiminimi, extending in front of the tubercle.

Anterior tubercle and the roughened area in front of it provide attachment to the short plantar ligament, and the rough slip between the three tubercles affords attachment to the long plantar ligament. [18]

Is rough and almost flat; it contains the peroneal tubercle, which lies between the tendons of two peronii. The tubercle gives attachment to a slip from the inferior peroneal retinaculum. The calcaneofibular ligament is attached about one centimeter behind the tubercle, occasionally marked by a round elevation. [19]

The function of the human hind foot in everyday gait, and more significantly in running or excessive weight bearing, predisposes its structure to be biomechanical and environmental stresses that often produce the pathology. [20]

The exact cause of painful heels is still uncertain; many theories were postulated to clarify this.

Hick's an English anatomist, postulated that a windlass mechanism due to metatarsophalangeal dorsiflexion can cause tension on the origin of the plantar fascia (figure 2); this tightening of the cable elevates the longitudinal arch, in so doing, places traction on the origin of the plantar fascia, another finding that supports this theory is that the most dense, unyielding section of the plantar aponeurosis originates from the location on the tuberosity of the calcaneus where the most common point of local tenderness is found during physical examination.

The most interesting theory is nerve entrapment syndrome involving the nerve branch to the abductor digiti minimi branch of the lateral plantar nerve. Baxter and Thigpen, in 1984, first described the role of entrapment syndrome as a cause. [21]

The course and ramification pattern of the lateral plantar nerve was studied by Solomon M.A. et al. in a serial section from four fetal feet dissection from 34 adult feet, with special reference to the so-called first branch. This branch was found in all of the observed fetal and adult specimens; from its originating point, the nerve run immediately distally to the medial process of the calcaneal tuberosity in a lateral direction to the proximal part of abductor digiti minimi muscle during its course of the branch gives two branches, one of them penetrates some time the insertion of quadratus Plantae muscle, whereas in adult feet it always sends fibers to the periosteum around the medial process of calcaneal tuberosity and the long plantar ligament, the other innervate the flexor digitorum brevis muscle, the site of possible entrapment is located between the abductor hallucis muscle and the medial head of the quadratus plantae muscle. [22]

There is strong evidence that the nerve is of the mixed type consisting of sensory fibers for the quadratus plantae, flexor digitorum brevis, and abductor digiti minimi muscles, which may explain the characteristic pain complaint of the heel pain syndrome. [23]

The occurrence of a stiff fascia perforated by the nerve branch or bursa around the insertion of the plantar aponeurosis as has been described and which was forward as a possible cause of heel pain. In 1987 Kenzora described the role of the nerve in the causation of pain and presented a preliminary report of a direct surgical approach for decompression. Schon, Glennon, and Baxter did electro-diagnostic studies to document entrapment neuropathy. [24]

Patients and Methods

Between November 2010 to May 2012, 50 patients complaining of inferior heel pain were treated in AL-Kadhimaya teaching hospital. There were 30 females and 20 males; the main presenting symptoms were pain on the inferno-medial aspect of the heel, exacerbating by prolonged weight-bearing and in the morning following sleep. The age of the patients ranged between 23-58 years. Bilateral heel pain was presented in 10 patients in our series. Therefore the overall number of heels treated in our series was 60 heels. All of the patients were treated first conservatively by rest, anti-inflammatory drugs, and local corticosteroid injection. Thirteen patients showed no response, so we advised them for surgery; 12 patients out of 13 agreed to surgery and were treated by plantar fascial release. The histories included name, Age, Sex, occupation, duration, Side affected, past history, Site of pain, Exacerbating factors, Relieving factors, history of local injection, and Previous operation. General examination: For systemic symptoms (exclude an-kylosing spondylitis, Reiter's disease, gout, and diabetes mellitus). The foot: - was examined as a whole for predisposing factors of heel pain (flat foot, pes cavus). Thirteen patients need surgery because of failure of conservative treatment, 12 of them agreed to the operation, and one refused; preoperatively, the patients informed us that we will not excise the spur, explaining that the spur is the result and not the cause of the problem. Longitudinal medial incision on the medial aspect of the heel 3-4 cm starts from about 1cm from the level of the posterior edge of the medial malleolus and extends distally along the junction of plantar and medial skin.

Dissection of soft tissue so that the medial third of the plantar fascia can be identified using a right-angled retractor. Under direct vision, the plantar fascia is divided completely. Two-Three drill holes at the medial aspect of the calcaneum were done. Release the tourniquet, and good haemostasis was done; closure of the skin with interrupted non-absorbable suture (silk 1/0) over a drain. Bulke compression dressing and finally,

back slab applied. Antibiotic injection (Cefatoxime 1gm/day) for two days followed by an oral antibiotic(Keflex 500mg/6 hourly) for another five days, removal of the drain done within 24 hours post-operatively, non-steroidal anti-inflammatory drugs and elevation of the limb to decrease pain and edema. The sutures and back slab were removed together after (14 days) and encouraged the patients to walk with two crutches. All 12 patients received the same antibiotic and the same analgesia. This paper aims to evaluate the result of surgical treatment in cases of plantar fasciitis which are not respond to conservative treatment.

Results

The study included 50 patients, 30 (60%) of them were females, and 20 (40%) were males, with a female/male ratio of 1.5/1 (Chart -1).

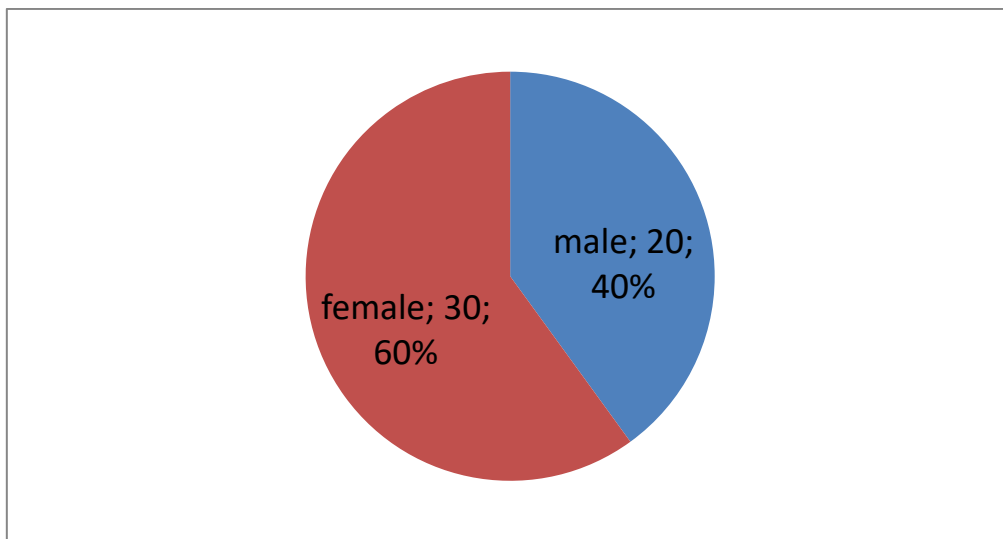


Chart 1- Male/female ratio

The age of the patients ranged between 23-58 years, with a mean age of 45 years; the mean age for females was 46, and for males was 42 years. The Occupations varied; 25 of the patients were housewives (50%), 15 patients were drivers (30%), five patients were Teachers (10%), and the other five patients were policemen (10%).

Table. 1- Occupations of patients

Percentage of patients	Occupation
50%	Housewife
30%	Driver
10%	Policeman
10%	Teacher

Regarding the presenting symptoms, ten patients (20%) had bilateral heel pain, while 40 patients (80%) had unilateral heel pain (Chart -2).

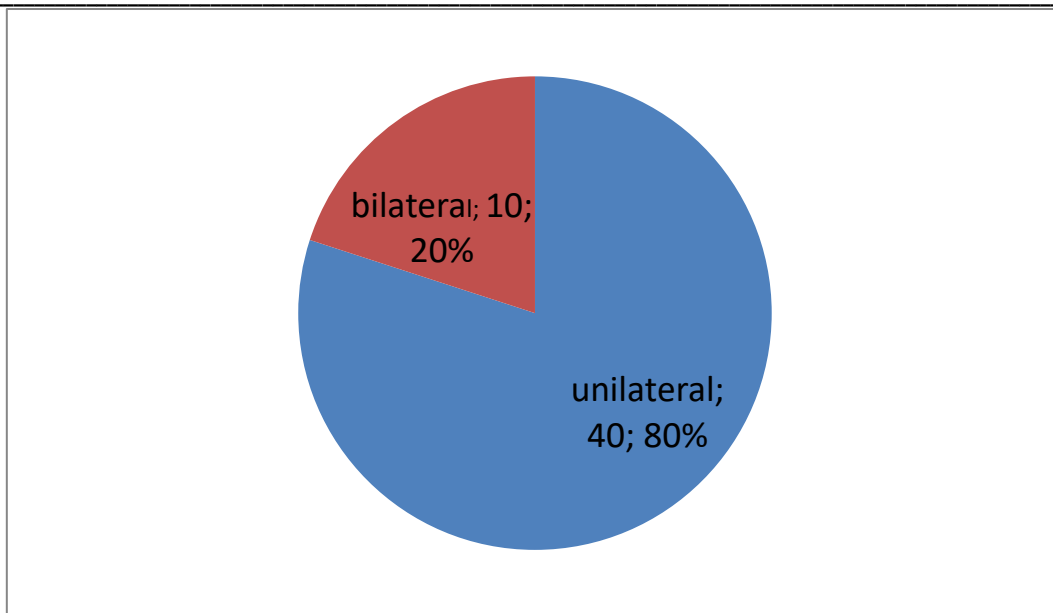
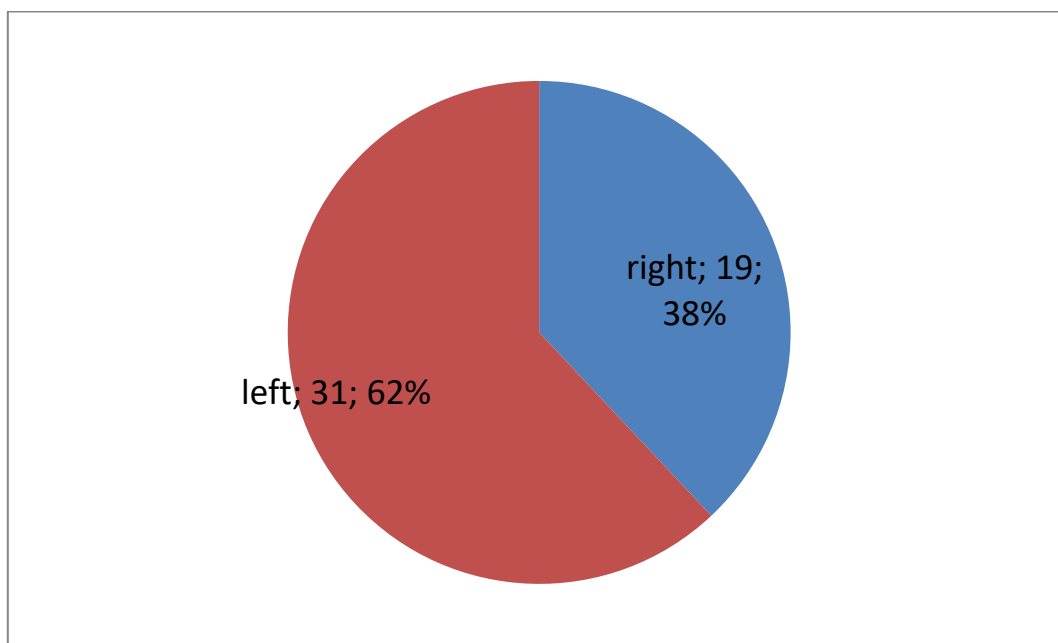


Chart 2- Laterality

Nineteen patients (38%) had right-sided heel pain, and 31 patients (62%) had left-sided heel pain (Chart-3).



Thirty-two patients (64%) had early morning pain, and the other 18 patients (36%) had pain after heavy work, walking for long distant, or standing for a long period of time and then resting.

Only six patients (12%) had a history of trauma prior to symptoms as precipitating factors, and ten patients (20%) complaining of parasthesia in one or both feet in association with the heel pain. Regarding other symptoms, 18 patients (36 %) had other complaints associated with heel pain as chronic low backache or knee pain. About family history, six patients (12%) had a positive family history of plantar fasciitis in their first-degree relatives. Physical examination of the feet showed that three patients (6%) had weak pulses in posterior tibial and dorsalis pedis arteries, two patients (4%) had abnormally high arch (pes cavus), three patients (6%) had flat foot diagnosed clinically and on the radiographic basis, An x-ray (AP and lateral views) was taken for all patients; 42 heels (70 %) showed bony spurs, 18 heels (30%) showed no bony abnormality (Chart (4)). X-ray showed calcaneal spure.

All patients were followed up for 3 -16 months with a mean period of follow-up of about four months. Regarding treatment, 29 patients (58 %) respond very well to rest, a course of 4-6 weeks of non-steroidal

anti-inflammatory; 8 patients (16 %) respond well to local steroid injection of 40 mg Methylprednisolone after the failure of controlling symptoms by non-steroidal anti-inflammatory for three months, 13 patients (26%) showed the failure of controlling the symptoms by no steroidal anti-inflammatory and local injection of steroid (after six months), those patients advised for. Surgery (Chart (5)). Twelve patients out of 13 accepted the idea of operation, 9 of them (75%) showed complete relieve of symptoms after surgery (good result), two patients (17%) showed mild improvement with pain after heavy exercise (fair result), and one patient (8%) showed persistent pain (poor result). Chart (6) Regarding complications, one patient suffered from post-operative superficial wound infection (8%). The most important complication encountered in our study was persistent heel pain which occurred in one patient (8%). No other complication had been occurred.

Discussion

Plantar fasciitis is a common problem faced almost daily in our orthopedic clinic, and it is not easy to satisfy the patients with curative treatment in a short period of time. It is characterized by deep pain in the plantar aspect of the heel, particularly on arising from bed; although the pain often subsides after a few steps, in some patients, the pain will persist for a long period. [25]

Management of inferior heel pain needs assessment of predisposing factors like overweight and seronegative disorders. In our study, out of 50 patients suffering from plantar fasciitis, 60% were females, and 40% were males. [26]

Baxter (31) reported a higher incidence of female involvement (70%), studies of Batt 66% females (32), and Hamdan 64.5% females (33).all are consistent with our study. Higher incidence of plantar fasciitis in females may be due to the problem of being overweight. [27]

The mean age of patients in our study was 44 years, which was consistent with the study of Batt, 45.7 years; the mean age of patients in the study of Hamdan and Baxter was 48 years; those ages are active and liable for plantar fasciitis because of a long time of standing and walking which exert great tension on the plantar fascia. 20% of our cases presented with bilateral heel pain, which was consistent with the study of Furey (29.1%) (2), Chi gwanda (34) had 36%, while Hamdan reported 39.6% bilateral symptoms. [28]

Regarding associated abnormalities, two patients (4%) had high arch feet, and three patients (6%) had flat feet. In the study of Osstro, who chose 40 patients with plantar fasciitis there were 3% had high arch foot, and 10% had flat feet (35). Patients with systemic diseases had been excluded from our study.

Regarding treatment, 37 patients (74%) respond to conservative treatment, while 13 patients (26%) had no response to conservative treatment. Therefore they were advised to undergo surgery, and 12 of them accepted surgery. [29]

Nine patients out of 12 (75%) undergoing surgery had a good result (pain-free) which was consistent with the study of Martti (70%) (36); Samarco(28) had a 92% good result after surgery. 17% of patients undergoing surgery in our study showed fair results (pain after heavy exercise), while 8% showed poor results (persistent pain). Per-operative drilling of calcaneum showed to be effective in post-operative heel pain relieves, which may be due to reduced intra-osseous pressure by decreasing venous congestion.

Regarding complications, 6% showed superficial wound infection, which was treated conservatively by rest and antibiotics for seven days.

In Batt's study, there was a 3% incidence of superficial wound infection, and 9% had parasthesia and numbness. Post-operative back slab for two weeks is important to decrease post-operative pain and to facilitate soft tissue healing. [30]

Conclusion

- 1- Complete division of plantar fascia has the advantages of complete relief of symptoms in 75% of cases and preventing recurrence.
- 2- Drilling of calcaneum had a beneficial effect in post-operative pain relief by decreasing intra-osseous pressure. (Probably by decreasing the venous congestion)
- 3- Back-slab had a rule of pain relieve and soft tissue healing post-operatively

References

1. Liden B, Simmons M, Landsman AS. A retrospective analysis of 22 patients treated with percutaneous

- radiofrequency nerve ablation for prolonged moderate to severe heel pain associated with plantar fasciitis. *J Foot Ankle Surg.* 2009;48:642–7.
2. Cole C, Seto C, Gazewood J. Plantar fasciitis: evidence-based review of diagnosis and therapy. *Am Fam Physician.* 2005;72:2237–42. [PubMed] [Google Scholar]
 3. Riddle DL, Pulisic M, Pidcoe P, Johnson RE. Risk factors for plantar fasciitis: a matched case-control study. *J Bone Joint Surg Am.* 2003;85-A:872–7.
 4. Hossain M, Makawana N. “Not Plantar Fasciitis”: The differential diagnosis and management of heel pain syndrome. *Orthopaedics and Trauma.* 2011;25 (3):198–206.
 5. Roxas M. Plantar fasciitis: Diagnosis and therapeutic considerations. *Altern Med Rev.* 2005;10:83–93. [PubMed] [Google Scholar]
 6. Chundru U, Liebeskind A, Seidelmann F, Fogel J, Franklin P, Beltran J. Plantar fasciitis and calcaneal spur formation are associated with abductor digiti minimi atrophy on MRI of the foot. *Skeletal Radiol.* 2008;37:505–10. [PMC free article] [PubMed] [Google Scholar]
 7. Johal KS, Milner SA. Plantar fasciitis and the calcaneal spur: Fact or fiction? *Foot Ankle Surgery.* 2012;18:39–41. [PubMed] [Google Scholar]
 8. Irving DB, Cook JL, Menz HB. Factors associated with chronic plantar heel pain: a systematic review. *J Sci Med Sport.* 2006;9:11–22. [PubMed] [Google Scholar]
 9. McPoil TG, Martin RL, Cornwall MW, Wukich DK, Irrgang JJ, Godges JJ. Heel pain-plantar fasciitis: clinical practice guidelines linked to the international classification of function, disability, and health from the orthopaedic section of the American Physical Therapy Association. *J Orthop Sports Phys Ther.* 2008;38:A1–18. [PubMed] [Google Scholar]
 10. Stuber K, Kristmanson K. Conservative therapy for plantar fasciitis: a narrative review of randomized controlled trials. *JCCA.* 2006;50:118–33. [PMC free article] [PubMed] [Google Scholar]
 11. Thomas JL, Christensen JC, Kravitz SR, Mendicino RW, Schuberth JM, Vanore JV, et al. The diagnosis and treatment of heel pain: a clinical practice guideline-revision 2010. *J Foot Ankle Surg.* 2010;49:S1–19. [PubMed] [Google Scholar]
 12. Alvarez-Nemegyei J, Canoso JJ. Heel pain: diagnosis and treatment, step by step. *Cleve Clin J Med.* 2006;73:465–71. [PubMed] [Google Scholar]
 13. Aklirat M, Sen C, Günes T. Ultrasonographic appearance of the plantar fasciitis. *Clin Imaging.* 2003;27:353–7. [PubMed] [Google Scholar]
 14. Saber N, Diab H, Nassar W, Razaak HA. Ultrasound-guided local steroid injection versus extracorporeal shockwave therapy in the treatment of plantar fasciitis. *Alexandria J Med.* 2011;48:35–42. [Google Scholar]
 15. Wearing SC, Smeathers JE, Sullivan PM, Yates B, Urry SR, Dubois P. Plantar fasciitis: Are pain and fascial thickness associated with arch shape and loading? *Phys Ther.* 2007;87:1002–8. [PubMed] [Google Scholar]
 16. Fabrikant JM, Park TS. Plantar fasciitis (fasciosis) treatment outcome study: Plantar fascia thickness measured by ultrasound and correlated with patient self-reported improvement. *Foot (Edinb)* 2011;21:79–83. [PubMed] [Google Scholar]
 17. Gudeman SD, Eisele SA, Heidt RS, Jr, Colosimo AJ, Stroupe AL. Treatment of plantar fasciitis by iontophoresis of 0.4% dexamethasone. A randomized, double-blind, placebo-controlled study. *Am J Sports Med.* 1997;25:312–6. [PubMed] [Google Scholar]
 18. Porter D, Barrill E, Oneacre K, May BD. The effects of duration and frequency of Achilles tendon stretching on dorsiflexion and outcome in painful heel syndrome: a randomized, blinded, control study. *Foot Ankle Int.* 2002;23:619–24. [PubMed] [Google Scholar]
 19. DiGiovanni BF, Nawoczenski DA, Lintal ME, Moore EA, Murray JC, Wilding GE, et al. Tissue-specific plantar fascia stretching exercise enhances outcomes in patients with chronic heel pain. A prospective, randomized study. *J Bone Joint Surg Am.* 2003;85-A:1270–7. [PubMed] [Google Scholar]
 20. Rompe JD, Cacchio A, Weil L, Jr, Furia JP, Haist J, Reiners V, et al. Plantar fascia-specific stretching versus radial shock-wave therapy as initial treatment of plantar fasciopathy. *J Bone Joint Surg Am.* 2010;92:2514–22. [PubMed] [Google Scholar]
 21. Ribeiro AP, Trombini-Souza F, Tessutti VD, Lima FR, João S, Sacco IC. The effects of plantar fasciitis

- and pain on plantar pressure distribution of recreational runners. *Clin Biomech (Bristol, Avon)* 2011;26:194–9. [PubMed] [Google Scholar]
22. Kampa RJ, Connell DA. Treatment of tendinopathy: is there a role for autologous whole blood and platelet-rich plasma injection? *Int J Clin Pract.* 2010;64:1813–23. [PubMed] [Google Scholar]
 23. Maier M, Steinborn M, Schmitz C, Stähler A, Köhler S, Pfahler M, et al. Extracorporeal shock wave application for chronic plantar fasciitis associated with heel spurs prediction of outcome by magnetic resonance imaging. *J Rheumatol.* 2000;27:2455–62. [PubMed] [Google Scholar]
 24. Sorrentino F, Iovane A, Sutera R, Tona GL, Lagalla R. How to address the treatment of idiopathic plantar fasciitis with mini-invasive techniques: HRUS criterion. *Ultrasound Med Biol.* 2009;35:s30. [Google Scholar]
 25. Thomas JL, Christensen JC, Kravitz SR, et al. American College of Foot and Ankle Surgeons Heel Pain Committee. The diagnosis and treatment of heel pain: a clinical practice guideline—revision 2010. *J Foot Ankle Surg.* 2010;49 (3 suppl): S1-S19.
 26. Flanigan RM, Nawoczinski DA, Chen L, Wu H, Digiovanni BF. The influence of foot position on stretching of the plantar fascia. *Foot Ankle Int.* 2007;28 (7):815-822.
 27. Owens BD, Wolf JM, Seelig AD. Risk factors for lower extremity tendinopathies in military personnel. *Orthop J Sports Med.* 2013;1 (1). doi:10.1177/2325967113492707.
 28. Riddle DL, Pulisic M, Pidcoe P, Johnson RE. Risk factors for plantar fasciitis: a matched case-control study. *J Bone Joint Surg Am.* 2003;85-A (5):872-877.
 29. Pfeffer G, Easley M, Frey C, Hintermann B, Sands A. *Operative Techniques: Foot and Ankle Surgery.* Philadelphia, PA: Saunders;2010;709-719.
 30. Banerjee R, Chao JC, Taylor R, Siddiqui A. Management of calcaneal tuberosity fractures. *J Am Acad Orthop Surg.* 2012;20 (4):253-258. doi:10.5435/JAAOS-20-04-253.