

Leiomyosarcoma of the kidney with massive thrombosis of the inferior vena cava: a clinical case and a review of the literature

G. G. Khakimova^{1,3}, V. S. Surkova², G. A. Khakimov³, Zh.B. Sadullaev³,
Sh. G. Khakimova^{1,2}

1. Tashkent Pediatric Medical Institute; Uzbekistan, 100140 Tashkent, street Bogishamol, 223
 2. Moscow Research Institute of Oncology named after P.A. Herzen - branch of the Federal State Budgetary Institution "National Medical Research Center for Radiology" of the Ministry of Health of the Russian Federation; Russia, 125284 Moscow, 2nd Botkinskiy proezd, 3;
 3. Nano Medical Clinic; Uzbekistan, 100069 Tashkent, Chimboy st. 2A
- Contact: Khakimova Gulnoz Golibovna hgg_doc@mail.ru.

Abstract: Leiomyosarcoma (LMS) is a rare malignant tumor of smooth muscle origin that usually arises from soft tissues, reduced due to smooth muscle or vessel walls of venous origin. Renal leiomyosarcomas arise from the smooth muscle tissues of the renal pelvis, renal capsule, or renal vessels, and are most commonly encountered. This article presents clinical cases of diagnosis and surgical treatment of renal leiomyosarcoma found in the renal pelvis, complicated by extended thrombosis of the vena cava inferior (VCI).

Key words: leiomyosarcoma of the kidney, thrombosis, vena cava inferior.

Introduction. Soft tissue sarcomas are a rare group of malignant tumors that develop from different types of connective tissue, which are heterogeneous mesenchymal neoplasms, including more than 70 histological subtypes [1]. The incidence of leiomyosarcomas (LMS) is about 0.05% of the total number of malignant neoplasms, about 0.5% of all sarcomas in adults, and 45% of retroperitoneal tumors [2-4]. LMS of the kidney is more common in women with an increase in incidence with increasing age of patients [5]. Renal leiomyosarcoma is an understudied tumor originating from the renal vasculature, renal veins, pelvic muscles, smooth muscle elements of the renal capsule [6,7]. According to its morphological structure, LMS of the kidney is characterized by fascicular, plexiform/unsystematic growth of spindle-shaped, epithelioid and pleomorphic cells. According to the degree of differentiation, highly and poorly differentiated tumors are distinguished [8]. The ability to invade venous vessels with the formation of tumor venous thrombosis, which spreads along the direction of venous blood flow from the intrarenal tributaries to the renal (RI) and inferior vena cava (IVC) veins up to the right parts of the heart, is a specific feature of kidney formation. Despite advances in drug therapy, surgery remains the only effective treatment for renal pelvic inflammatory disease with tumor venous thrombosis.

Clinical case. The patient, born in 1959, was admitted to the Nano Medical Clinic with complaints of pain in the lumbar region on the right, general weakness since June 2022. From the anamnesis: with the above complaints, she went to the clinic at the place of residence, where the following was performed: ultrasound of the abdominal organs dated September 22 .22: Right-sided urethrohydronephrosis. Education in the projection of the right kidney. The formation of the retroperitoneal space. CT scan of the abdominal organs dated 24.09.22. with v.v contrasting: In the lower half of the right kidney, an irregularly shaped, multi-nodular, heterogeneous solid structure with fuzzy uneven contours, density +26+45+55, is determined. In the phase of contrast enhancement, there is an intense inhomogeneous accumulation of a contrast agent, with the presence in the structure of chaotically located vessels from the right renal artery and the infrarenal aorta. The mass, 10x13.2x11.5 cm in size, spreads extraorganically with signs of germination in the IVC, with the spread of a thrombus in the lumen of the latter 5 cm proximal to the level of the renal veins and 8 cm caudal. The formation grows into the n/3 of the ureter, spreading into the anterior pararenal space, grows into Gerota's fascia, infiltrates the ascending colon and the 12th duodenum, closely adhering to the psoas major

muscle. The surrounding tissue is infiltrated. Paraaortally, in the mesentery of the large and small intestines, the greater omentum, multiple lymph nodes are determined, 8 mm in size. (Figure 1)

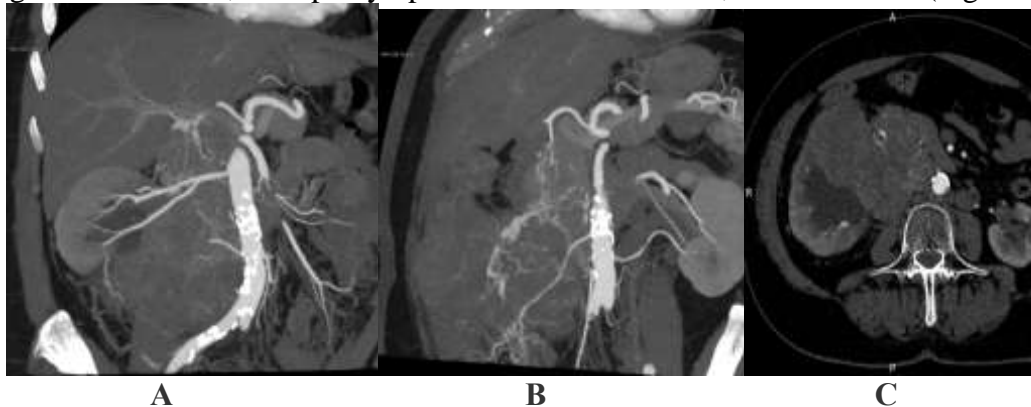


Figure 1. CT scan of the abdominal cavity with IV contrast in the arterial phase (A, B) in the portal phase (C):

A) in the retroperitoneal space on the right, an irregularly shaped multinodular volumetric formation with clear, uneven contours emanating from the right kidney is determined, pushing the abdominal aorta contralaterally. Against the background of formation, the inferior vena cava is not visualized. Feeding arteries, outgoing and renal arteries, abdominal aorta and superior mesenteric artery are determined.

B) violation of the dichotomy of the feeding arteries with the germination of the formation of the kidney in the right side wall of the abdominal cavity.

C) a volumetric formation 9.0x12.5x11.9 cm in size, growing into the inferior vena cava almost throughout its entire length with the formation of a tumor thrombus, dimensions in the lumen of the vein 45x54x83 mm. 27.09.22 a biopsy of the tumor of the right kidney was performed at the place of residence. Histopathological examination No. 100774\22 dated 09/28/22: Leiomyosarcoma, G-2. The patient applied to Nano Medical Clinic on her own. General condition at admission: moderate severity, clear consciousness, limited active position. The skin and mucous membranes are clean, pale pink. In the lungs, vesicular breathing is absent on both sides. Heart sounds are clear, rhythmic. A \ d - 120 \ 70 mm Hg, Pulse - 85 beats / min. The tongue is moist, coated with a whitish coating. The abdomen is soft, painful in the mesogastric region and in the right iliac region. There are no peritoneal phenomena. Stool and diuresis regular. Based on examinations: X-ray of the chest dated September 30, 22: signs of chronic bronchitis. Bone scintigraphy dated 01.10.22: data on specific damage to the bones of the skeleton was not received Dopplerography of the arteries of the abdominal aorta from 03.10.22: In the abdominal cavity from the right half with a transition to the left to the level of the sigmoid intestine, an irregularly shaped space-occupying formation is visualized, echononhomogeneous, with a fuzzy contour, 160.0x63.0x84.0 mm in size. Compresses the abdominal aorta. The contours of the vessel are uneven, clear, the vessel is passable. The aorta at the level of the bifurcation, the superior mesenteric artery, the inferior mesenteric artery, the celiac trunk behind the formation is not clearly located. Endoscopy dated 03.10.22: catarrhal gastroduodenitis. Colonoscopy dated 03.10.22: The mucous membrane is hyperemic. In the zone of the hepatic flexure, there is compression of the lumen, possibly from the outside, the device is not passable. In the lumen there are clots of intestinal contents. Radioisotope examination of the kidneys with a technician dated 04.10.22: Left kidney: Max. accumulation time -5 min. The half-life before the introduction of furosemide is 10.19 minutes, the half-life after the introduction of furosemide is 16.28 minutes. Right kidney: Time max. accumulation -23 min. The elimination half-life before the introduction of furosemide has not come. The half-life after the introduction of furosemide has not come. Conclusion: A sharp violation of the secretory and excretory function of the right kidney. (pic 2)

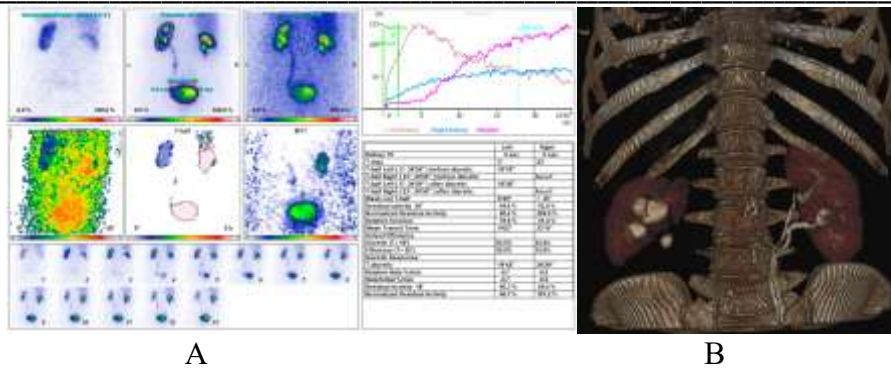


Fig 2. A) Examination of kidney function with Tc 99m MAG isotope 3 Dose 2 mCi. Relative functional involvement of the kidneys: Left kidney - 78.6%. Right kidney - 21.4%. Relative functional involvement of the kidneys: Left kidney - 78.6%. Right kidney - 21.4%. Scintigraphically, the location of both kidneys is normal, the contours are even, clear, the right kidney is reduced in size. The curves are asymmetrical. Radiographically: the accumulation of radiopharmaceuticals in the right kidney is slow, excretion did not occur during the study. C) Excretory phase of abdominal CT: Functional involvement of the left kidney with doubling of the pyelocaliceal system and the left ureter. The right kidney is not functioning.

A clinical diagnosis was established: Cancer of the right kidney with in-growth into the wall of the IVC, tumor thrombus, stage III cT4NxM0. Complications: Ureterohydronephrosis on the right. Pain syndrome. On the basis of clinical and instrumental data, the decision of the council on 06.10.22. performed surgical treatment for health reasons in the amount of right-sided nephroadrenalectomy, resection of the wall of the inferior vena cava, thrombectomy, appendectomy. Revision: in the right half of the abdomen there is a tumor conglomerate emanating from the retroperitoneal space, including the right kidney, right adrenal gland, mesentery of the ascending section and the hepatic flexure of the colon, retroperitoneal tissue. The tumor pushes and squeezes the right half of the colon up and to the left. The tumor passes medially beyond the midline. Palpation to identify the hilum of the right kidney, the condition of the renal vessels, the inferior vena cava, the abdominal aorta is not possible due to the large size of the formation. The formation is dense, the surface is bumpy in places, with decay and ulceration, limited displacement. The liver and mesentery of the small intestine are not changed, the left kidney is of normal size. There were no signs of dissemination of the tumor process. The process is recognized as locally widespread and complicated. Protocol of the operation: the tumor conglomerate was mobilized in an acute way. The right ureter is mobilized, ligated and transected above the mouth of the bladder. The adrenal artery and vein were treated separately. In the lumen of the inferior vena cava, a tumor thrombus was determined, 6.5 cm long. The proximal border of the tumor thrombus in the lumen of the IVC was located 5 cm above the confluence of the left renal vein. The distal border ended above the bifurcation of the iliac vessels, 8.0 cm long. The total length of the tumor thrombus was 14.0 cm. The renal artery and vein were treated separately. The end of the appendicular process is intimately soldered to the tumor, where there was a rasad and ulceration. A pathologically compacted area at the end of the appendicular process is identified by palpation. An appendectomy was performed. The drug has been removed. The inferior vena cava, the left renal vein were taken on a tourniquet, mobilized along the proximally and distally retreating from the tumor thrombus. In the projection of the renal veins, the anterior wall of the inferior vena cava was dissected for 9.0 cm. The wall of the inferior vena cava was sharply mobilized, and the tumor thrombus was removed. An excision was made.

The section of the walls of the inferior vena cava is intimately soldered to the tumor thrombus. (Fig. 4.5) The lumen of the inferior vena cava was sanitized with 0.9% NaCl, the integrity of the wall of the inferior vena cava was restored with atraumatic vascular sutures No. 5.0. The blood flow has been restored. Hemostasis control. Performed dissection of tissue with lymph nodes and lymphatic vessels along the abdominal aorta and inferior vena cava. The abdominal cavity is carefully sanitized and drained in the right hypochondrium and right iliac region. Macropreparation: Right kidney with formation and perirenal adipose tissue with a total size of 18x15x11 cm. Kidney with a formation measuring 15x15x11 cm. Formation of a dense consistency, gray-whitish color, size 11x13x11 cm, uneven color, hemorrhages. (Fig. 6,7,8) Tumor thrombus in the lumen of the inferior vena cava, length 14.0 cm, diameter of the proximal part 6.5 cm, distal

part 4.5 cm. Tumor thrombus of a dense consistency of whitish light. On the section, the tumor originates from the lower pole of the right kidney, affects it subtotally. Blood loss -1600 ml. The duration of the operation is 3:45 min. The postoperative course is smooth. Healing by primary intention. The patient was discharged from the hospital after 8 days. Pathomorphological conclusion No. 101812/22 dated 9.10.22: leiomyosarcoma of the right kidney, G2; 12 lymph nodes with reactive hyperplasia; obturating tumor thrombus; portal vessels and ureter without tumor lesions. IHC No. 102220329050 dated 10/11/22: leiomyosarcoma of the right kidney. Reactions for CD34, SMA, Desmin in tumor cells are positive; negative for CD117, DOG1, S100, STAT6, Myogenin, MyoD1. The Ki67 proliferation index is 70%. SDHB is preserved.(Fig.9)

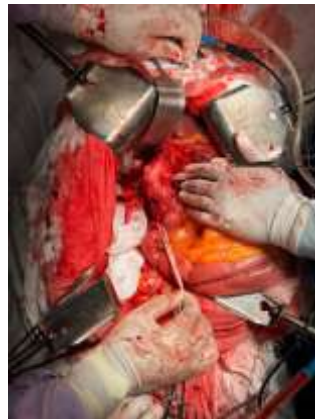

Fig 3. Intraoperative photo: the lumen of the inferior vena cava is filled with a tumor thrombus. The inferior vena cava proximally and distally retreating from the tumor thrombus was taken on a tourniquet. The left renal vein was isolated on a tourniquet.

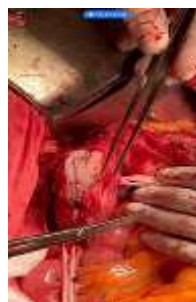

Fig 4. Intraoperative photo: the anterior wall of the inferior vena cava is dissected. A tumor thrombus is visible in the lumen.

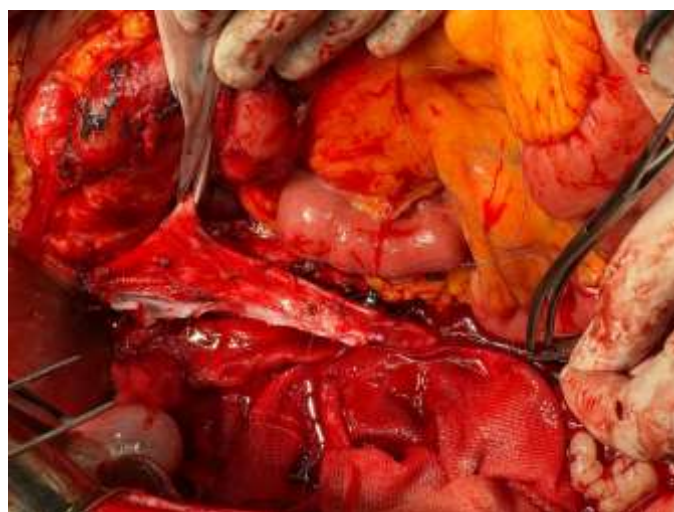

Figure 5. Intraoperative photo: lumen of the inferior vena cava after removal of the tumor thrombus.

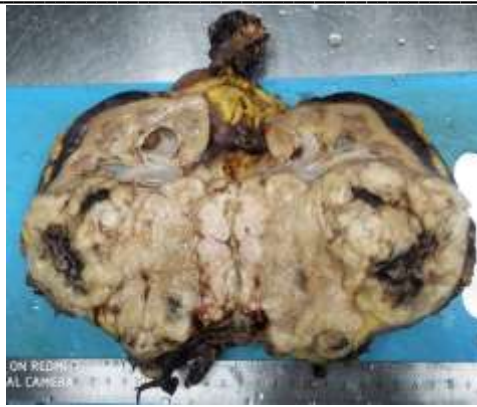

Figure 6. Right kidney with tumor. When cut (in the preserved area), the cortical and brain parts are distinguishable. The cortex is light brown, the medulla is dark brown. The calyces are cystically dilated.

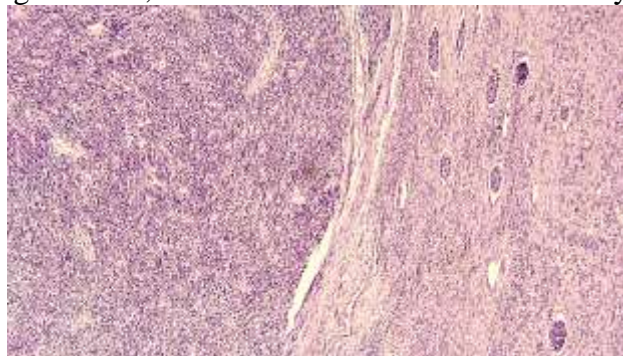
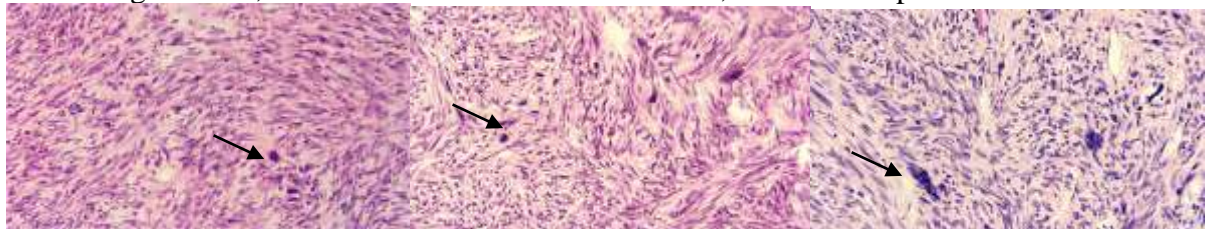


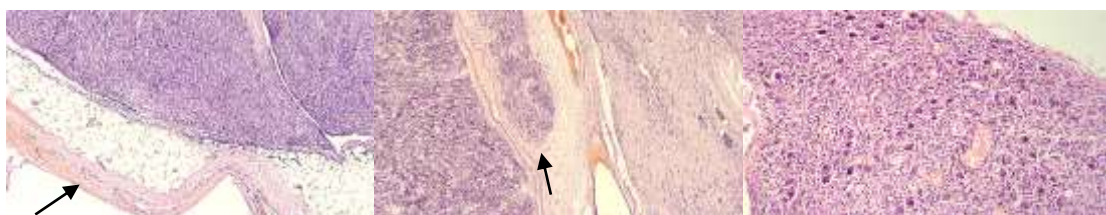Fig.7. Microscopic picture of the tumor of the right kidney. Tumor kidney tissue (left) at the border with the unaffected area (right). The tumor tissue consists of multidirectional, intersecting bundles, moiré structures formed by polymorphic, spindle-shaped cells with elongated atypical nuclei on the border with the renal tissue with small anemic glomeruli, some of them in a state of sclerosis, thickened capsules.



A

B

C

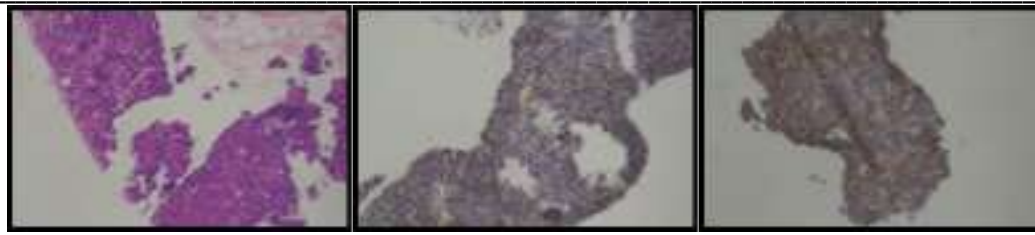


D

E

F

Rice. 8. Leiomyosarcoma (tumor thrombus) (x20). A-B Tumor tissue is represented by multidirectional bundles of elongated smooth muscle cells, with rounded or oval polymorphic nuclei with numerous mitoses. Among which there are random accumulations of large polymorphic, with large ugly, hyperchromic one (A, B) or several nuclei with many mitoses (C). The formation is surrounded by a connective tissue capsule with hemorrhages in the wall (D). Large blood-filled arteries in the middle of the tumor tissue (right) and on the border with the unchanged part of the renal tissue (left). (E). Adjacent renal tissue with small anemic glomeruli, some of them in a state of sclerosis, thickened capsules. (E)



H&E

CD34 (QBENd-10)

DESMIN (GM 007)

Rice. 9. Immunohistochemical examination of the right kidney tumor ($\times 200$). In tumor cells, diffuse and pronounced staining with hematoxylin and eosin (HE), expression of CD34 hematopoietic cells and desmin is detected.

Discussion. Leiomyosarcoma of the kidney does not have any specific clinical and radiological signs; at present, the diagnosis is confirmed by the result of a morphological study after the surgical intervention. Clinical manifestations are nonspecific: pain in the abdomen and lumbar region, hematuria. The main problem is that traditional instrumental research methods do not allow sufficient differential diagnosis of LMS and renal cell carcinoma. Renal vein LMS is often mistaken for renal cell carcinoma prior to surgery [9]. To date, treatment options for LMS of the kidney are the subject of discussion, however, according to a few foreign studies, the method of choice, given the high potential of the tumor to local recurrence, is radical nephrectomy, which provides better oncological control and 5-year survival rates [10, 11]. Our clinical example, where, taking into account the prevalence of the process, according to vital indications, radical nephrectomy was performed on the right, thrombectomy, and paraaortic lymphadenectomy are highly complex operations that required resection of the wall of the main vessel with angioplasty, requiring adequate anesthetic and transfusiological support. Under conditions of IVC occlusion, a hypertrophied collateral bed in the form of thin-walled, randomly located veins further complicates the situation.

Complete removal of a thrombus without the risk of fragmentation and embolism requires confident control of all large vessels in the area of intervention. Do not ignore the lumbar veins, bleeding from which can be very intense. Attempts to “blindly” remove a thrombus (for example, with a balloon probe) carry the additional risk of leaving residual thrombotic masses containing tumor cells on the vein wall. This significantly increases the likelihood of generalization of the tumor process and local recurrence [12]. Thus, the radical removal of a thrombus creates prospects for the recovery of patients. According to a number of clinical observations [13-15], adjuvant/neoadjuvant chemotherapy/radiation therapy can be used in the treatment of PMLS. However, no randomized trial has demonstrated a significantly significant improvement in survival rates. Thus, according to P. Beardo et al., a 69-year-old patient with LMS of the kidney after radical nephrectomy with lymphadenectomy without adjuvant chemotherapy has no signs of progression and relapse for 5 years [16]. The works of G. Bath [17], Y. Kwon [18] describe observations of patients with renal leiomyosarcoma after radical nephrectomy with a follow-up of 3 months and no signs of recurrence. Leiomyosarcoma of the kidney usually has an aggressive course of the disease with a poor prognosis [19]. The main prognostic factor is total surgical resection. In the case of R0 resection, the 5-year recurrence-free survival can be 60%. In addition, for low-grade and high-grade tumors, the 5-year disease-free survival rate is 90% and 30%, respectively [19,20]. For R1 resection, adjuvant chemotherapy is indicated [21]. The most preferred chemotherapy regimen is the gold standard treatment for soft tissue sarcomas, an anthracycline/ifosfamide-containing regimen [22]. Also, a phase II study described the possibility of using tyrosine kinase inhibitors in patients with relapsed and refractory soft tissue sarcomas, mainly with leiomyosarcoma, liposarcoma, and fibrous histiocytoma [23].

Conclusion. Leiomyosarcoma of the kidney is a rare tumor where the gold standard of treatment is surgery. There are complicated forms of renal leiomyosarcoma in the form of venous thrombosis of the inferior vena cava, which require adherence to the principles of oncosurgery and the inclusion of elements of reconstructive surgery.

Bibliography.

1. Hui J.Y.C. Epidemiology and etiology of sarcomas. *Surg Clin North Am* 2016;96(5):901–14. DOI:10.1016/j.suc.2016.05.005.
2. Guerrero M.A., Cross C.A., Lin P.H. et al. Inferior vena cava reconstruction using fresh inferior vena cava allograft following caval resection for leiomyosarcoma: midterm results. *J Vasc Surg* 2007;46(1):140–3.
3. Laskin W.B., Fanburg-Smith J.C., Burke A.P. et al. Leiomyosarcoma of the inferior vena cava: clinicopathologic study of 40 cases. *Am J Surg Pathol* 2010;34(6):873–81.
4. Tilkorn D., Hauser J., Ring A. et al. Leiomyosarcoma of intravascular – a rare tumor entity: clinical pathological study of twelve cases. *World J Surg Oncol* 2010;8:103–10.
5. Niceta P, Lavengood RW, Jr, Fernandes M, Tozzo PJ. Leiomyosarcoma of kidney. Review of the literature. *Urology* 1974;3:270-7
6. Lopez-Beltra A., Menendez C.L., Montironi R., Cheng L. Rare tumors and, tumor-like conditions in urological pathology. DOI: 10.1007/978-3-319-10253-5.
7. Павлов А.Ю., Гармаш С.В., Исаев Т.К. и др. Современные представления о лейомиосаркомах вен забрюшинного пространства. Обзор клинических случаев. *Онкоурология* 2016;12(2):92–6. [Pavlov A.Yu., Garmash S.V., Isaev T.K. et al. Current view: leiomyosarcoma of the veins of the retroperitoneum. Case histories review. *Onkourologiya = Cancer Urology* 2016;12(2):92–6. (In Russ.)]. DOI: 10.17 650/1726-9776-2016-12-2-92-96.
8. WHO classification of tumours of the urinary system and male genital organs. Eds.: H. Moch, P.A. Humphrey, T.M. Ulbright, V.E. Reuter. 4th edn.
9. Деметьев И.О., Чайков В.С., Троянов А.В. и др. Редкая злокачественная опухоль почки – лейомиосаркома почечной вены (клинический случай). *Онкоурология* 2022;18(1):143–50. DOI: 10.17650/1726-9776-2022-18-1-143-150.
10. Iwata J., Fletcher C.D. Immunohistochemical detection of cytokeratin and epithelial membrane antigen in leiomyosarcoma: a systematic study of 100 cases. *Pathol Int* 2000;50(1):7–14. DOI: 10.1046/j.1440-1827.2000.01001.x.
11. Deyrup A.T., Montgomery E., Fisher C. Leiomyosarcoma of the kidney: a clinicopathologic study. *Am J Surg Pathol* 2004;28(2): 178–82. DOI: 10.1097/0000478-200402000-00004.
12. Р.А.Хвастунов, А.А. Юсифова Рак почки с массивным тромбозом нижней полой вены. Хирургическое лечение. *Вестник ВолГМУ* 2017г., №2(62) DOI 10.19163/1994-9480-2017-2(62)-136-140
13. Кригер А.Г., Берелавичус С.В., Сон А.И. и др. Хирургическое лечение неорганных забрюшинных опухолей. *Хирургия. Журнал им. Н.И. Пирогова* 2017;(1):15–26. [Kriger A.G., Berelavichus S.V., Son A.I. et al. Surgical treatment of retroperitoneal masses. *Khirurgiya. Zurnal im. N.I. Pirogova = Pirogov Russian Journal of Surgery* 2017;(1):15–26. (In Russ.)]. DOI: 10.17116/hirurgia2017115-26.
14. Raut C.P., Pisters P.W. Review retroperitoneal sarcomas: combined-modality treatment approaches. *J Surg Oncol* 2006;94(1):81–7. DOI: 10.1002/jso.20543.
15. Young S., Amirali S., Christopher S. et al. Renal leiomyosarcoma: case report and review of the literature. *World J Nephrol Urol* 2015;4(2):213–7. DOI: 10.14740/wjnu214w.
16. Beardo P, José Ledo M, Jose Luis RC. Renal leiomyosarcoma. *Rare Tumors*. 2013 Sep 4;5(3):e42. doi: 10.4081/rt.2013.e42. PMID: 24179654; PMCID: PMC3804817.
17. Bhat G., Nelivigi G., Shivalingaiah M. et al. Primary renal leiomyosarcoma: case report and literature review/ *African Journal of Urology*, 2011, Vol.17, №1:15-17
18. Kwon Y.S., Salmasi A., Sejong C. et al. Renal leiomyosarcoma% case report and review of the literature/ *World Journal of nephrology and urology*, 2015, Vol.4, №2:213-217
19. Miettinen M, Fetsch JF. Evaluation of biological potential of smooth muscle tumours. *Histopathology* 2006;48:97-105

-
20. Bevilacqua RG, Rogatko A, Hadju SI, Brennan MF. Prognostic factors in primary retroperitoneal soft-tissue sarcomas. *Arc Surg* 1991;126:328-34
 21. Raut CP, Pisters PW. Retroperitoneal sarcomas: combined-modality treatment approaches. *J Surg Oncol* 2006;94:81-7
 22. Zafar R., Manthri S., Shurbaji M.S. Renal leiomyosarcoma. StatPearls Publishing, 2021.
 23. Mahmood T, Agresta S, Vigil CE, et al. Phase II study of sunitinib malate, a multi-targeted tyrosin kinase inhibitor in patients with relapsed or refractory soft tissue sarcomas. Focus on three prevalent histologies: leiomyosarcoma, liposarcoma and malignant fibrous histiocytoma. *Int J Cancer* 2011;129:1963-9

E-mail: hgg_doc@mail.ru. ORCID: <https://orcid.org/0000-0002-4970-5429>