

Successful Treatment of Multiple Liver Abscesses on the Background of Diabetes Mellitus

Matmurotov K.J., Pulatov U.I., Khamdamov S.A.,
Yakhshibaev S.Sh., Yakubov I.Y.
Tashkent Medical Academy, Tashkent, Uzbekistan

Annotation. Despite the successes of modern surgery, bacterial abscesses remain one of the most complex complications in surgical hepatology [4]. Traditionally used methods of surgical interventions are quite remote and, often, insufficiently adequate, especially with multiple abscesses, as well as with the development of sepsis. Combination with minimally invasive techniques (in the form of interventions under the control of radiation navigation (ultrasound, X-ray), endoscopy and laparoscopy) can significantly improve the results of treatment of this category of patients [2].

Key Words: Liver, modern surgery

Liver abscesses are a serious disease characterized by the presence of solitary or multiple cavities in the liver with a pyogenic capsule [6]. The frequency of cases of liver abscesses is stably high and does not decrease, according to various sources - 0.08-2% of patients hospitalized in a surgical hospital [1,3,4,11]. Over the past 20 years, the number of minimally invasive, open surgical interventions on the bile ducts with the maintenance of stents and transfer drainages has also increased dramatically, which has increased the number of cholangiogenic liver abscesses. Unfortunately, the results of surgical treatment of abscesses remain unsatisfactory. The number of complications is up to 55%, mortality reaches 12-38% - with single abscesses, up to 77-90% - with multiple abscesses [3,4,10].

There are three directions in the treatment of liver abscesses: 1) conservative therapy, 2) open surgical interventions, 3) minimally invasive manipulations under the control of ultrasound, computer tomography or videolaparoscopy. In the last decade, it has been proven that minimally invasive interventions in the treatment of liver abscesses are the most effective [2]. Their advantage is low-traumatic, the possibility of performing the procedure in any unit of the hospital and under local anesthesia, which is important in the treatment of serious patients undergoing treatment in intensive care units. In addition, minimally invasive technologies are economically viable. The experience of many authors has shown that puncture and drainage of an abscess under ultrasound guidance are easy to perform and effective methods of treatment, thanks to which the number of open operations has decreased, the number of postoperative complications has decreased, and the duration of the patient's stay in the hospital has decreased [5,6,7].

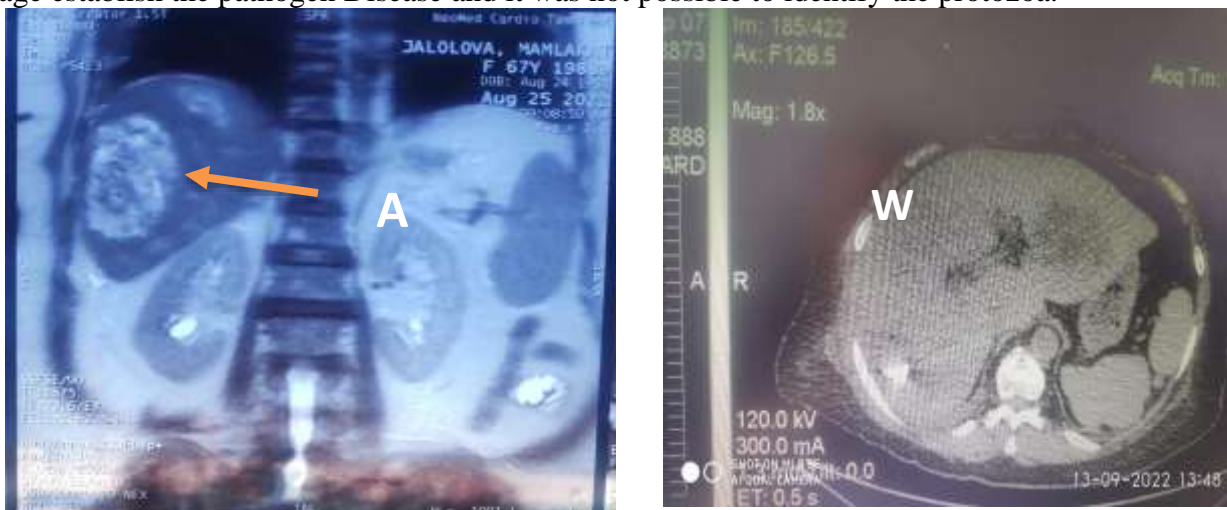
In this report, we give a clinical example of the effectiveness of the use of puncture-draining techniques for the treatment of multiple liver abscesses.

Clinical observation. Patient Dzhabolova M 67 years old, in August 2022, against the background of complete well-being, felt a deterioration in general well-being, the appearance of heaviness and pain in the right hypochondrium of a pulling nature, an increase in body temperature with chills, increasing general weakness. According to urgent indications, the patient was hospitalized in the department of purulent surgery and surgical complications of diabetes mellitus at the Moscow profile clinic of the Tashkent Medical Academy, where the diagnosis was established: Basic multiple focal lesions of the liver and right-sided hydrothorax. Companion: with a chronic diabetes type 2, severe course. Upon admission, the general condition of the patient is severe, the position is passive, inhibited. Complaints of severe general weakness, pain in the right hypochondrium, fever, loss of appetite. Hemodynamics is unstable, with a tendency to hypotension (BLOOD PRESSURE - 90/60 mm Hg) The abdomen is soft, moderately painful in the right hypochondrium.

In blood tests, pronounced leukocytosis ($15.9 \times 10^9 / l$), hypochromic anemia, hyperamino transferemia, hyperbilirubinemia are noted. According to ultrasonography, in the projection of the V and VIII segments of the liver, destruction cavities with a diameter of 3.5 to 6 cm are determined (Fig. 1. A). On

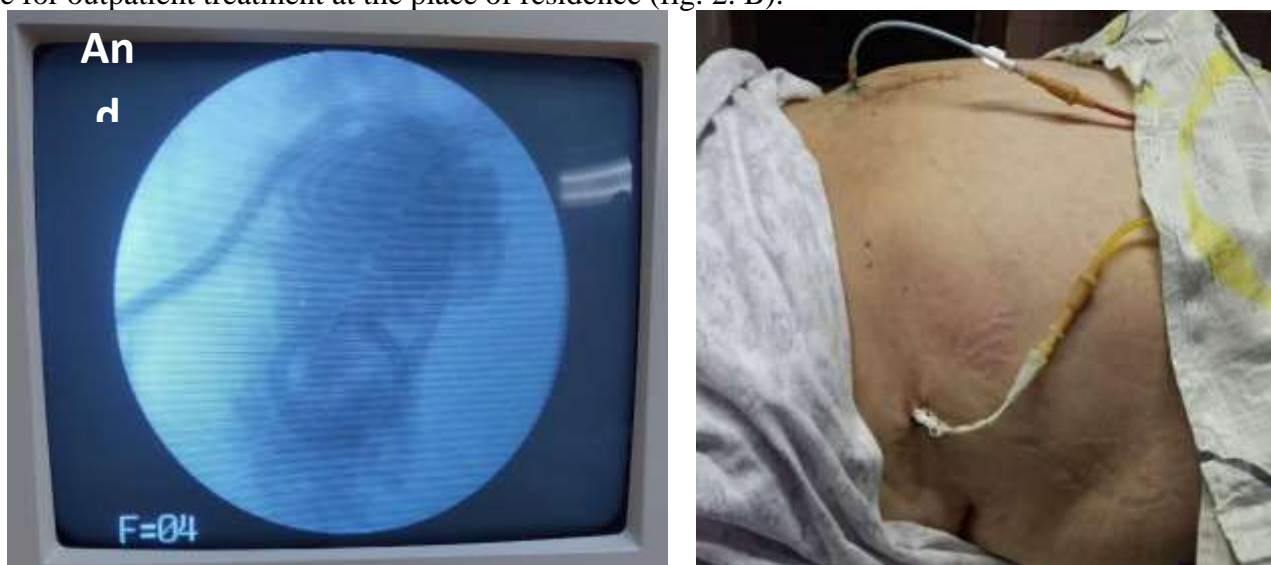the last day of inpatient treatment, the patient underwent percutaneous drainage of the abscess of the right lobe of the liver under the ultrasonic navigation of transdermal drainage with a diameter of 9 F. At the same time, about 150 ml of creamy purulent discharge was released. The abscess cavity is sanitized daily with antiseptic solutions. The complex of therapeutic measures of conservative treatment included adequate antibacterial, hepatotropic, detoxification and symptomatic therapy.

In dynamics with standing boIt has stabilized, clinical signs endogenous intoxication syndrome decreased by 4-day treatment. On microbiological examination of the discharged, which was taken during drainage establish the pathogen Disease and it was not possible to identify the protozoa.



Rice. 1. Volumetric formation of the right lobe of the liver (A) and the affected area of the left lobe (II segment).

On the 3rd day after drainage flooroSTI liver abscess appeared signs biliary excretion with an admixture of pus. On the 5th day from the moment of hospitalization there was a deterioration in the patient's condition. There were signs of an increase in body temperature (up to 39 C) nausea with vomitouch and leukocytosis. With control ultrasound and computed tomography examinations was diagnosed additional pathological hearth ino II segment of the liver (fig. 1. B), which is rubbedthe installation of additional percutaneous percutaneous peregastric drainage. During repeated bacteriological examination of the discharge from the drains, a culture was isolated *Enterobacter aeruginosa*, чувствительная Was to meropenem. Patient started purposeful antibiotic therapy. As the syndrome of systemic inflammatory response is stopped and stopped excreta purulent discharge through the drains with Reducing Size Cavities Liver in control studies with contrast and on Ultrasonicsohm Research painDischarged home with drainage tube for outpatient treatment at the place of residence (fig. 2. B).



Rice. 2. The volume of the pathological formation (A) and the installed drainage tubes (B).

The drainage tubes were removed on the 45th day after drainage and follow-up examination. In the immediate postoperative period (2 months of eggs) and long-term periods (6 months), no signs of relapse and pathological foci in the liver were detected on computed tomographic examination.

Discussion. The choice of a strategy for minimally invasive or open surgical methods for the treatment of multiple large purulent liver abscesses is still controversial. The main method of treating liver abscesses for a long time was the opening and drainage of the abscess cavity through laparotomic access. However, lethality in open surgical interventions are high and reach 20-30%, and with the development of complications it doubles. Over the past three decades, the development of modern imaging diagnostic methods (ultrasound, CT, MRI) has contributed to the wider use of minimally invasive methods of sanitation of liver abscesses. The advantages of puncture and drainage techniques are low invasiveness, no need for general anesthesia, as well as the possibility of rapid sanitation already at the stage of primary diagnosis. The effectiveness of treatment reaches 69-98%. Our observation describes the high efficiency of the minimally invasive technique of sanitation of multiple liver abscesses, which made it possible to avoid open traumatic surgery.

Thus, the introduction of modern minimally invasive chirgi technologies in the treatment of liver abscesses in combination with adequate antibiotic therapy allows to avoid traumatic large resection surgical methods and achieve recovery of patients. From this point of view, this method of treatment is optimal and further improvement in terms of localization of the process, taking into account concomitant diseases, the timing and features of the surgical technique requires further study and pushes us to new research.

List Of Literature:

1. Abdominal surgery. National Leadership / ed. by I.I. Zatevakhina, A.I. Kiriyyenko, V.A. Kubishkina. M.: GEOTAR-MED, 2016. 903 s.
2. Arkhangelsky V.V., Bedin V.V., Kulyshev V.O. et al. Minimally invasive methods of treatment of liver abscesses under ultrasound control // Ultrasonic functional diagnostics. 2004. № 1. S. 150-151.
3. Akhaladze G.G. Key issues of surgical treatment of liver abscesses // Annals of surgical hepatology. 2012. T. 17. № 1. S. 53-60.
4. Basos F. Liver abscesses: diagnostics, treatment / F. Basos, N.A. Maistrenko // Materials of the Plenum of the Board of the Association of Surgeons - Hepatologists of Russia and CIS Countries. Perm', 2001. S. 82-83.
5. Modern tactics in the treatment of bacterial abscesses of the liver / V.A. Ovchinnikov, A.A. Malov, S.V. Akulenko // Med. almanac. Surgery. 2013. T. 29. № 5. pp. 99-103.
6. Shapovalyants S.T. Abscesses of the liver / S.T. Shapovalyants, A.T. Mylnikov // Clinical surgery : national leadership: v 3 t. / pod red. B.S. Savelyeva, A.I. Kiriyyenko. – M.: GEOTAR – Media. – 2009. – S. 188-196.
7. Chung D. R., Lee H., Park M. H. et al. Fecal carriage of serotype K1 Klebsiella pneumonia ST23 strains closely related to liver abscess isolates in Koreans living in Korea // Eur. J. Clin. Microbiol. Infect. Dis. 2011. Vol. 31, № 4. P. 481-486.
8. Ferraioli G., Garlaschelli A., Zanaboni D. et al. Percutaneous and surgical treatment of pyogenic liver abscesses: observation over a 21-year period in 148 patients // Dig. Liver Dis. 2008. Vol. 40, № 8. P. 690-696.
9. Fung C. P., Lin Y. T., Lin J. C. et al. Klebsiella pneumoniae in gastrointestinal tract and pyogenic liver abscess // Emerg. Infect. Dis. 2012. Vol. 18, № 8. P. 1322-1325.
10. Lubbert C., Wiegand J., Karlas T. Therapy of liver abscesses // Visceral Medicine. 2014. Vol. 30, № 5. P. 334-341.
11. Vogl T. J., Esifan F. Pyogenic liver abscess: interventional versus surgical therapy: technique, results and indications // Rofo. 2001. Vol. 173, N 7. P. 663-667.